

**ΜΕΤΑΠΤΥΧΙΑΚΟ ΠΡΟΓΡΑΜΜΑ ΣΠΟΥΔΩΝ:**

**“ΕΛΑΧΙΣΤΑ ΕΠΕΜΒΑΤΙΚΗ ΧΕΙΡΟΥΡΓΙΚΗ,  
ΡΟΜΠΟΤΙΚΗ ΧΕΙΡΟΥΡΓΙΚΗ ΚΑΙ ΤΗΛΕΧΕΙΡΟΥΡΓΙΚΗ”**

**ΕΘΝΙΚΟ ΚΑΙ ΚΑΠΟΔΙΣΤΡΙΑΚΟ ΠΑΝΕΠΙΣΤΗΜΙΟ ΑΘΗΝΩΝ**

**ΙΑΤΡΙΚΗ ΣΧΟΛΗ**

**ΔΙΠΛΩΜΑΤΙΚΗ ΕΡΓΑΣΙΑ**

**ΘΕΜΑ: ΚΑΤΑΓΡΑΦΗ ΚΑΙ ΑΞΙΟΛΟΓΗΣΗ ΤΕΧΝΙΚΩΝ ΕΝΤΟΠΙΣΜΟΥ ΤΩΝ  
ΕΝΔΟΦΥΤΙΚΩΝ ΝΕΦΡΙΚΩΝ ΟΓΚΩΝ ΣΤΙΣ ΕΛΑΧΙΣΤΑ ΕΠΕΜΒΑΤΙΚΕΣ  
ΝΕΦΡΟΣΥΝΤΗΡΗΤΙΚΕΣ ΕΠΕΜΒΑΣΕΙΣ. ΣΥΣΤΗΜΑΤΙΚΗ ΑΝΑΣΚΟΠΗΣΗ ΤΗΣ  
ΒΙΒΛΙΟΓΡΑΦΙΑΣ**

**ΜΕΤΑΠΤΥΧΙΑΚΟΣ ΦΟΙΤΗΤΗΣ:**

**ΠΑΠΑΡΙΔΗΣ ΣΠΥΡΙΔΩΝ**

**A.M.: 20181031**

**ΕΠΙΒΛΕΠΩΝ: ΚΑΘΗΓΗΤΗΣ κ. ΣΤΡΑΒΟΔΗΜΟΣ ΚΩΝΣΤΑΝΤΙΝΟΣ**

**ΑΘΗΝΑ**

**ΑΠΡΙΛΙΟΣ 2022**



**POSTGRADUATE PROGRAM:**  
**«MINIMALLY INVASIVE SURGERY**  
**ROBOTIC SURGERY & TELESURGERY»**

**NATIONAL AND KAPODISTRIAN UNIVERSITY OF ATHENS**  
**MEDICAL SCHOOL**

**MASTER THESIS**  
**RECORD AND APPRAISAL OF ENDOPHYTIC TUMOR LOCALIZATION**  
**TECHNIQUES IN MINIMALLY INVASIVE KIDNEY-SPARING PROCEDURES. A**  
**SYSTEMATIC REVIEW.**

**POSTGRADUATE STUDENT:**  
**PAPARIDIS SPYRIDON**

**A.M.: 20181031**

**SUPERVISOR: PROFESSOR KONSTANTINOS STRAVODIMOS**

**ATHENS**  
**APRIL 2022**

## **Περίληψη**

**Εισαγωγή/Σκοπός:** Καταγραφή και αξιολόγηση της αποτελεσματικότητας των τεχνικών που χρησιμοποιούνται για τον διεγχειρητικό εντοπισμό των ενδοφυτικών νεφρικών όγκων.

**Υλικό και Μέθοδος:** Πραγματοποιήθηκε σύνθετη αναζήτηση στις βάσεις δεδομένων: PubMed, Cochrane Library, Web of Science και Google Scholar μέχρι τον Αύγουστο 2020. Τα κριτήρια καταλληλότητας για ένταξη στην μελέτη ορίστηκαν σύμφωνα με τις οδηγίες PRISMA. Υπολογίστηκε ο λόγος σχετικών πιθανοτήτων, OR (95 % CI), για την επιτυχία εντοπισμού, την τεχνική επιτυχία, τα θετικά χειρουργικά όρια και την υποτροπή, στους πλήρως ενδοφυτικούς όγκους. Ο κίνδυνος μεροληψίας (Risk of Bias), εκτιμήθηκε με χρήση του εργαλείου ROBVIS.

**Αποτελέσματα:** 77 μελέτες χρησιμοποιήθηκαν για την σύνθεση των αποτελεσμάτων, οι οποίες περιλάμβαναν 1,317 ενδοφυτικούς όγκους, με τους 758 να είναι ενδοπαρεγχυματικοί. 356 ενδοφυτικοί όγκοι αντιμετωπίστηκαν λαπαροσκοπικά και 598 ρομποτικά, και ο εντοπισμός τους πραγματοποιήθηκε με χρήση μεθόδων βασισμένων στην υπερηχογραφική καθοδήγηση, τον εκλεκτικό αρτηριακό εμβολισμό, την CT διπλής πηγής (dual-source), την επεμβατική σηματοδότηση, την 3D εκτύπωση, αλλά και διάφορων παραλλαγών της τεχνικής επαυξημένης πραγματικότητας. Η επιτυχία εντοπισμού ήταν 97.8-100%, τα θετικά χειρουργικά όρια 0-12.5 % (ενδοπαρεγχυματικοί όγκοι: 95 % CI; 0.255-1.971, OR 0.709 στην λαπαροσκοπική και 95 % CI ; 0.379-3.109, OR 0.086 στην ρομποτική μερική νεφρεκτομή), υποτροπή 0-3.9 % (ενδοπαρεγχυματικοί όγκοι: 0% υποτροπή στην λαπαροσκοπική και 95 % CI ; 0.0917-2.25, OR 0.454, στην ρομποτική μερική νεφρεκτομή), και επιπλοκές 0-60 % . 363 όγκοι, αντιμετωπίστηκαν με επεμβάσεις κατάλυσης, χρησιμοποιώντας τεχνικές εντοπισμού όπως CT-καθοδήγηση, ινοπτική θερμική καταγραφή, εκλεκτικό αρτηριακό εμβολισμό, υπερηχογραφική καθοδήγηση και επεμβατική σηματοδότηση. Η τεχνική επιτυχία ήταν 33.4-100 % (ενδοπαρεγχυματικοί όγκοι: 95 % CI ; 0.00157-2.060, OR 0.0569 για επεμβατικές και 95 % CI ; 0.598-13.152, OR 2.804 για μη επεμβατικές τεχνικές εντοπισμού) και η υποτροπή 0-20%.

**Συμπέρασμα:** Οι τεχνικές διεγχειρητικού υπέρηχου, εμφάνισαν αποδεκτά ογκολογικά αποτελέσματα και ικανότητα εντοπισμού στην λαπαροσκόπηση και τις ρομποτικές επεμβάσεις. Οι τεχνικές επαυξημένης πραγματικότητας, δεν υπερέχαν των συμβατικών τεχνικών. Η υπέρυθρη ακτινοσκόπηση με ενδοφλέβια χορήγηση πράσινου της ινδοκυανίνης, αποδείχθηκε ανεπαρκής για τον εντοπισμό αυτών των όγκων, αν και όταν χορηγήθηκε εκλεκτικά με αγγειογραφία, τα αποτελέσματα ήταν ενθαρρυντικά, όπως και στις υπόλοιπες τεχνικές βασισμένες στον αγγειογραφικό εμβολισμό. Η επεμβατική σηματοδότηση με διαδερμική τοποθέτηση, εντός του όγκου, σύρματος ή μεταλλικών πηνίων αγγειογραφίας βοήθησε στην ασφαλή και επιτυχή σηματοδότηση των ενδοπαρεγχυματικών ισοηχογενών όγκων, τα δεδομένα όμως ήταν ανεπαρκή για την ασφαλή εκτίμηση της αποτελεσματικότητας. Η CT καθοδήγηση, συνδυασμένη με υπέρηχο ή ινοπτική θερμική καταγραφή, στις επεμβάσεις θερμικής κατάλυσης, έδειξε αυξημένη τεχνική επιτυχία, σε αντίθεση με την μεμονωμένη υπερηχογραφική καθοδήγηση που εμφάνισε πτωχά αποτελέσματα.

**Λέξεις κλειδιά:** Τεχνικές κατάλυσης, Ενδοφυτικοί όγκοι, Νεφρός, Λαπαροσκόπηση, Ρομποτικές χειρουργικές επεμβάσεις

## **Abstract**

**Background/Aim:** Review and efficacy assessment of techniques used for intraprocedural endophytic renal mass localization.

**Materials and Methods:** Advanced search was carried out on PubMed, Cochrane Library, Web of Science and Google Scholar databases up to August 2020. Eligibility criteria were set, according to PRISMA statement. OR (95 % CI) for identification or technical success, positive margins and recurrence, were calculated for completely endophytic tumors. Risk of Bias was evaluated using ROBVIS tool.

**Results:** 77 studies used for result synthesis, including 1,317 endophytic tumors, with 758 of them completely endophytic. 356 endophytic tumors treated laparoscopically and 598 robotically, using ultrasound-based methods, transarterial embolization, dual-source CT, invasive signage, 3D printing, and augmented reality variations. Identification success was 97.8-100%, positive margins 0-12.5 % (completely endophytic: 95 % CI; 0.255-1.971, OR 0.709 in laparoscopic, 95 % CI ; 0.379-3.109, OR 0.086 in robotic partial nephrectomy), recurrences 0-3.9 % (completely endophytic: 0 recurrences in laparoscopic, 95 % CI ; 0.0917-2.25, OR 0.454, in robotic partial nephrectomy), and complications 0-60 % . 363 were treated with ablation techniques using CT-based methods, thermal monitoring, transarterial embolization, ultrasound guidance and invasive signage. Technical success was 33.4-100 % (completely endophytic: 95 % CI ; 0.00157-2.060, OR 0.0569 for invasive and 95 % CI ; 0.598-13.152, OR 2.804 for non-invasive localization techniques) and recurrences were 0-20%.

**Conclusion:** Ultrasound-based techniques showed acceptable identification success and oncologic outcomes in laparoscopic or robotic setting. Augmented reality, showed no superiority over conventional techniques. Near infrared fluoroscopy with intravenous indocyanine green, was incapable of endophytic tumor tracking, although when administered angiographic, results were promising, along with other embolization techniques. Percutaneous hook-wire or embolization coil signage, aided in safe and successful tracking of parenchymal isoechoic masses, but data are inadequate to assess efficacy. CT-guidance, combined with ultrasound or thermal monitoring, showed increased technical success during thermal ablation, unlike ultrasound guidance that showed poor outcomes.

### **Key Words:**

Ablation Techniques, Endophytic, Kidney, Laparoscopy, Neoplasms, Robotic Surgical Procedures

## Ευχαριστίες

Ευχαριστώ θερμά όλους τους καθηγητές, διδάσκοντες και προσωπικό του Π.Μ.Σ. “Ελάχιστα επεμβατική χειρουργική, Ρομποτική χειρουργική και Τηλεχειρουργική” για την ευκαιρία να εμβαθύνω στον τομέα της ελάχιστα επεμβατικής χειρουργικής, τόσο με τις νέες γνώσεις που αποκόμισα, όσο και με τις πρακτικές δεξιότητες που εξάσκησα κατά την διάρκεια της φοίτησής μου. Ευχαριστώ ιδιαίτερω τον Καθηγητή Χειρουργικής κ. Νικόλαο Νικητέα, τον Καθηγητή Ουρολογίας και επιβλέποντα κ. Κωνσταντίνο Στραβοδήμο, τον καθηγητή κ. Δημήτριο Δημητρούλη, τον Επίκουρο Καθηγητή κ. Γεράσιμο Τσουρούφλη, και τον συντονιστή του Π.Μ.Σ κ. Ελευθέριο Σπάρταλη για την καθοδήγηση και συμβολή τους στην ολοκλήρωση της διπλωματικής μου εργασίας. Ευχαριστώ το επιστημονικό περιοδικό Urology Journal (<https://journals.sbm.ac.ir/uroj/index.php/uj>) για την αποδοχή της εργασίας προς έκδοση και την δημοσίευση στο PubMed/Medline με την ακόλουθη παραπομπή: *Paparidis S, Spartalis E, Mavrigiannaki E, Ferakis N, Stravodimos K, Tsourouflis G, Dimitroulis D, Nikiteas NI. Record and Appraisal of Endophytic Tumor Localization Techniques in Minimally Invasive Kidney-Sparing Procedures. A Systematic Review. Urol J. 2022 Apr 20. doi: 10.22037/uj.v19i.7056. Epub ahead of print. PMID: 35466395.*

Επίσης, ευχαριστώ τον διευθυντή μου κ. Νικόλαο Φεράκη για την βοήθεια στην σύλληψη της ιδέας αυτής της εργασίας, τον κ. Αβραάμ Πουλιάκη για την πολύτιμη βοήθειά του στην στατιστική επεξεργασία των δεδομένων και την παιδοχειρουργό κ. Ελευθερία Μαυριγιαννάκη για την καθοριστική συμβολή της στη συγγραφή της εργασίας.

Τέλος, ευχαριστώ τον πατέρα μου Γεώργιο Παπαρίδη, την μητέρα μου Κλεοπάτρα Παπαρίδη και την αδερφή μου Μαρία-Ελένη Παπαρίδη, για τη διαχρονική βοήθεια, υπομονή και στήριξη τους.

# **Table of Contents**

<b>Introduction .....</b>	<b>8</b>
<b>Materials and Methods.....</b>	<b>9</b>
Eligibility Criteria .....	9
Search strategy.....	10
Data extraction .....	10
Quality assesment.....	10
Statistical analysis.....	11
<b>Results.....</b>	<b>12</b>
Laparoscopic Assisted Partial Nephrectomy (LPN).....	12
<i>Completely endophytic subgroup analysis for LPN.....</i>	<i>13</i>
Robotic Assisted Laparoscopic Partial Nephrectomy (RAPN).....	14
<i>Completely endophytic subgroup analysis for RAPN.....</i>	<i>16</i>
Radiofrequency Ablation (RFA).....	16
Cryoablation .....	17
Microwave Ablation (MWA).....	18
Irreversible Electroporation (IRE).....	18
<i>Completely endophytic subgroup analysis for thermal ablation.....</i>	<i>18</i>
High Intensity Focused Ultrasound (HIFU).....	19
<b>Discussion.....</b>	<b>19</b>
<b>Conclusion.....</b>	<b>23</b>
<b>References.....</b>	<b>23</b>
<b>Appendix A .....</b>	<b>36</b>
Detailed search string per database.....	36
Table 1. Results from studies regarding LPN for endophytic tumors. ....	38
Table 2. Results from studies regarding RAPN for endophytic tumors.....	39
Table 3. Results from studies regarding Ablation for endophytic tumors.....	40
Table 4. Meta Regression Analysis.....	41

<b>Appendix B.....</b>	<b>41</b>
Figure 1.....	41
Figure 2.....	42
Figure 3.....	43
Figure 4.....	44
Figure 5.....	44
Figure 6.....	45
Figure 7.....	46



## **Introduction**

Kidney-sparing procedures overran radical nephrectomy for treating small renal masses. European Association of Urology guidelines 2019, recommend partial nephrectomy for T1 renal cell tumors <sup>(1)</sup>. Not only kidney preservation is important but also maintenance of maximum parenchyma for better functional outcomes, especially in patients with impaired renal function, comorbidities or bilateral tumors <sup>(2)</sup>, indicating a shift from kidney to nephron-sparing procedures.

Minimally invasive nephron-sparing procedures were stratified by Gill 2003<sup>(3)</sup> into three categories: excision, probe ablation, non-invasive ablation. Excision methods include surgeries such as laparoscopic or robotic-assisted partial nephrectomy <sup>(4)</sup>. Probe ablation methods include RFA, Cryoablation, MWA and IRE <sup>(5,6)</sup>. Finally, non-invasive ablation procedures include HIFU and stereotactic body radiation ablation <sup>(5)</sup>.

Identification of endophytic renal masses, especially completely endophytic that acquire 3 points in the “(E)-endophytic/exophytic” parameter of R.E.N.AL nephrometry score <sup>(7)</sup>, can be challenging. Lack of haptic feedback in minimally invasive procedures and visual feedback when treating intraparenchymal masses, are obstacles in tumor localization.

Our rationale is to concisely present and evaluate endophytic tumor identification techniques described during minimally invasive nephron-sparing procedures. We aim to comprise a decision-making guide for the clinician, when treating endophytic and especially non-visible completely endophytic renal tumors.

## **Materials and Methods**

### ***Clinical question and Eligibility Criteria***

This review is based on a focused clinical question using P.I.C.O (Population, Intervention, Comparison, and Outcome) Worksheet and Search Strategy Protocol <sup>(8)</sup>. (P) Endophytic renal masses, (I) Minimally Invasive Kidney-sparing procedures, (C) Tumor localization techniques, (O) Presentation of recorded techniques and evaluation of efficacy and oncologic outcomes. Inclusion criteria were: 1) English language 2) Population: Renal masses characterized as endophytic, completely endophytic, intrarenal, totally intrarenal, intraparenchymal and parenchymal, 3) Study design: Randomized controlled trials and observational studies, as well as systematic

reviews/meta-analyses, reviews and case reports 3) Intervention: minimally invasive kidney-sparing treatments (laparoscopic or robotic partial nephrectomy, ablative methods and hybrid techniques). 4) Outcomes: Report, assessment or comparison of different invasive or non-invasive localization techniques used for signage of the aforementioned masses. Exclusion criteria were: 1) Animal, phantom, ex-vivo or cadaveric studies 2) Abstracts or conference announcements and electronic book publications. 3) Studies on upper tract urothelial masses.

### ***Information Sources and Search Strategy***

An advanced search was carried out on PubMed, Cochrane Library, Web of Science and Google Scholar databases up to August 2020, with the terms: kidney/renal/nephron sparing OR kidney/renal/nephron preserving OR laparoscopic/3D Laparoscopic/robotic/robotic assisted partial nephrectomy OR ablation OR minimal invasive AND endophytic OR intraparenchymal OR intrarenal OR parenchymal AND renal tumor/mass/lesion/cancer OR kidney tumor/mass/lesion/cancer. Keyword search with the terms: “tumor marking” “endophytic renal tumor” “minimal invasive” “kidney sparing” was performed synchronously in Google Scholar database. This study was conducted according to Preferred Reporting Items for Systematic Reviews and Meta-Analyses (PRISMA) statement 2009<sup>(9)</sup>.

PubMed and Cochrane Library search resulted in 429, Web of Science in 29 and Google Scholar search in 977 studies. 97 originated from references manual cross-searching in relevant articles. 1,498 studies were screened for eligibility after duplicate extraction. 1,234 studies initially excluded by title and abstract, 153 studies secondarily excluded, after full reading, due to eligibility criteria mismatch. Finally, 111 studies were included in our systematic review for evaluation. 77 studies, 1 multi-institutional prospective single arm, 6 prospective case-series, 5 prospective comparative and 59 retrospective and 6 case-reports, were included for narrative results presentation or subgroup analysis. Search results are summarized in PRISMA flow-diagram (Figure. 1).

### ***Data extraction and Risk of Bias assessment***

Data extraction was performed in duplicate and included study type and design, minimally invasive approach, identification method, identification and technical success for ablative techniques, number and size of tumors, marginal status, perioperative complications, recurrence and follow-up. Risk of bias was assessed using ROBVIS tool<sup>(10)</sup> based on ROBINS-I tool for assessing non-randomized studies of interventions<sup>(11)</sup>. Observational studies with inconclusive information, case reports and reviews were evaluated, although a priori considered

critically biased. Risk of bias was evaluated throughout seven domains: confounding, selection of participants, classification of interventions, deviations of intended interventions, missing data, measurement of outcomes, selection of the reported results. For each domain we used a judgment from low to serious. Results are presented in a traffic-light plot (Figure. 2).

### ***Result synthesis and Statistical Analysis***

Results presentation is mainly narrative. A meta-analysis was not performed due to heterogeneity of overall study population. Therefore, percentages of the outcome values for each variable instead of effect measures were calculated.

Statistical analysis, was performed for the distinctive subgroup of completely endophytic tumors (intraparenchymal, parenchymal, totally intrarenal, endophytic non-visible during surgery), which showed low clinical and methodological heterogeneity. Pooled Odds Ratios (OR) under random effects, using Cochran-Mantel-Haenszel test, were calculated with MedCalc-version 19.7.1 software, and forest-plots were used for presentation (Figures 3-7). Measured outcomes were, positive margins and recurrences for Laparoscopic and Robotic or technical success for Ablation procedures, due to adequacy of data. We have not used adjusted ORs, since they were not provided in all relevant studies and if applied, covariates were not the same in each study. All Tumor Localization techniques in Laparoscopic and Robotic procedures were non-invasive ultrasound-based, whereas in ablation procedures such techniques were heterogeneous (invasive and non-invasive) therefore separate analysis was performed respectively. Publication bias was assessed using Egger's linear regression test and Begg's rank test, and presented in funnel-plots (Figures 3-7). Statistical heterogeneity was quantified, using Cochran's Q test and  $I^2$  statistic index ( $P < .05$  as statistically significant,  $I^2 \leq 50\%$  for low heterogeneity). The latter was used to assess if the amount of variance across studies was likely to be real and not due to sampling errors. Results were presented along with forest-plots (Figures 3-7).

"R package meta" in R (programming language) was used to perform subgroup meta-regression analysis and determine sources of heterogeneity. Only confounding covariates present in all studies, either defined from authors of each study or determined according to our experience, were used for meta-regression. Results showed that positive margins in robotic approach negatively related to patient B.M.I. Successful Ablation was also

negatively related to the number of thermal Ablation Needles used, as concluded from the negative meta-regression slope (Table 4).

## **Results**

### ***Laparoscopic Assisted Partial Nephrectomy***

Data from 22 studies regarding 363 endophytic masses that underwent Laparoscopic Partial Nephrectomy (LPN), were collected (Table. 1).

Described techniques were, Intraoperative Ultrasound (IOUS) (n = 265), Intraoperative dual-source CT (DSCT) (n = 25), Three dimensional printing physical kidney model technique (3Dp k.m) (n = 5), Intraoperative ultrasound guidance combined with 22 Gauge needles for tumor delineation (needle-IOUS) (n = 3), Intratumoral CT-guided percutaneous Hook-Wire insertion for tumor signage (Hook-Wire) (n = 2), selective intra-arterial blue dye embolization (blue dye TAE) (n = 7), Augmented Reality (A.R.) (n = 54), Radio-Guided Occult Lesion Localization (ROLL) (n = 1).

Results on IOUS were extracted from retrospective comparative studies <sup>(12-15)</sup>, retrospective single arm studies <sup>(16-20)</sup> and a prospective case-series study <sup>(21)</sup>. Identification success rate was 100%, mean tumor size was 16-37 mm, positive margin rate was 1.96 % -12.5 % , recurrence rate was 0 % in a mean 3-39.2 months follow-up and complication rate was 15.2 % -60 % . Various observational studies <sup>(22-25)</sup> and reviews <sup>(26-29)</sup> highlighted the importance of IOUS for identification of intrarenal masses, precise delineation of size and depth, and presence of satellite renal masses or collecting system infiltration

DSCT was used in a retrospective study <sup>(30)</sup> for retroperitoneal LPN. Overall accuracy of feeding artery orientation was 93.6 % , tumor identification success was 100 % , no positive margins or recurrences occurred in a mean 18-month follow-up.

3Dp k.m <sup>(31)</sup> used markers orientated by anatomical landmarks, labeled on a kidney-model surface. Navigation intraoperatively was performed using kidney-model's distance measurements. Mean tumor size was 27.8 mm, treated with trans or retro peritoneal LPN. Identification rate was 100 % . No complications or positive margins were reported.

Needle IOUS assisted de novo identification of an unidentified intraparenchymal lesion with IOUS-only guidance. Neither positive surgical margins nor recurrences were reported in 27-month follow-up.

Hook-Wire was applied in 2 intraparenchymal tumors <sup>(32,33)</sup>. Identification success was 100 % , no complications or positive surgical margins were reported, and a 16-month follow-up in one case showed no recurrence.

Blue dye TAE, followed by super selective tumor embolization with glue or micro coils was presented in a prospective study <sup>(34)</sup>. No complications related to dye injection occurred nor positive surgical margins were present. All tumors were successfully embolized. Data regarding identification success were inconclusive. Early Follow-up imaging showed no recurrences.

A.R. summarizes a spectrum of techniques, all based on superimposing pre/intraoperative images, onto endoscopic scene. Intraoperative imaging or preoperative 3D-reconstructions can be registered within surgical view in three ways: 1) surface-based registration using a stylus or a range scanner tool, 2) manual registration using fiducials and markers, 3) 3D to 3D registration using stereoscopic robotic camera ability <sup>(35,36)</sup>. 10 masses were identified with Real-time imaging like cone-beam CT (CBCT) combined with fiducial aid technique <sup>(37-39)</sup>. CBCT helps resolving the tissue deformation issue, due to natural organ movement, that can cause imprecise image fusion <sup>(40)</sup>. 44 tumors were identified with 3D reconstructed preoperative image fused with 2D or 3D laparoscopic view <sup>(41-44)</sup>. Identification rate was 100% and no positive surgical margins were reported for both techniques. CBCT showed no complications while 3D reconstruction technique had 0-13.3 % complication rate.

ROLL successfully used gamma camera for one intraparenchymal tumor in an experimental setting <sup>(45)</sup>, this was the only case reported in English literature <sup>(46)</sup>.

### ***Completely endophytic subgroup analysis for LPN***

Data were extracted from 12 studies (6 retrospective comparative, 3 retrospective single arm, 3 case-reports) <sup>(12,42,13,31,41,18,14,15,20,32,33,45)</sup>. From 239 tumors, 17 were identified with A.R., 5 with 3Dp k.m, 211 with IOUS, 3 with needle IOUS, 2 with Hook-wire and 1 with ROLL. Intraparenchymal growth showed no correlation to identification success among methods. All techniques had 100 % successful identification rates both for intervention and control groups. Odds Ratio was 95 % CI ; 0.255-1.971, OR 0.709, P = .510, with low

heterogeneity ( $Q = 1.355$ , 95 % CI ; 0.00-41.36,  $I^2$  0.00 % ,  $P = .8553$ ) for positive margins with IOUS guidance or A.R. navigation in LPN (Figure. 3).

Positive margins with IOUS guidance had 95%CI; 0.0519-6.701, OR 0.590 in LPN compared to RAPN. Consecutive studies showed 95 % CI; 0.0201-5.756, OR 0.340 ; 95 % CI ; 0.179-3.589, OR 0.790 and 95 % CI ; 0.0251-7.191, OR 0.425 for an exophytic compared to an intrarenal mass to have positive margins. Positive margins for 3D reconstruction A.R. techniques, such as 3D-medical image reconstructing and guiding system (MIRGS), over control group had 95 % CI ; 0.116-115.805, OR 3.667 for totally intraparenchymal tumors. Local recurrence rate using IOUS, was 0 % in 5 comparative studies <sup>(12), (13), (14), (20), (41)</sup> with a mean 12-39.2 months follow-up, but data were insufficient for statistical analysis.

### ***Robotic Assisted Laparoscopic Partial Nephrectomy***

Data from 27 studies regarding 598 endophytic masses that underwent Robotic Assisted Laparoscopic Partial Nephrectomy (RAPN), were collected (Table. 2). IOUS was the cornerstone of identification methods during RAPN <sup>(47,48)</sup>. 365 masses were identified with IOUS. Other sonography-based methods were, IOUS combined with frozen sample biopsies from tumor bed (frozen-sample IOUS) ( $n = 161$ ), Intraoperative laparoscopic Ultrasound enhanced with color Doppler modality (LDU) ( $n = 7$ ) and Intraoperative Contrast Enhanced Ultrasound (CEUS) ( $n = 5$ ). Apart from ultrasonography, embolization techniques such as iodized oil Trans arterial embolization in tumor feeding-artery (iodized oil TAE), TAE with Near infrared Fluoroscopy imaging using indocyanine Green (TAE NIRF-ICG) ( $n = 10$ ), A.R. ( $n = 42$ ) and percutaneous placement of embolization coils inside the mass for tumor signage (embolization coils) ( $n = 1$ ) were used.

Endophytic tumor size in IOUS techniques <sup>(12),(49-62)</sup> was 23-32,5mm. Identification success rate was 100%, complication rate varied 0-21.8% and positive margin rate ranged 0 -6.1 % . Recurrence rate varied among studies 0-1.6 % , in 8-48 months follow-up.

Frozen sample IOUS studies <sup>(63-65)</sup> included masses sized 26-28mm. Identification success rate was 97.8 % - 100 % . Positive margin rate was 0-9.6 % . Complication rate was 21.9 % -32.7 % , and distal or local recurrence rate was 2.2 % -3.9 % in a mean 48-59 months follow-up.

LDU <sup>(61, 66)</sup>, was used, not only to locate tumor but to identify resection margin, tumor distance from collecting system <sup>(67)</sup> and to track adjacent vessels <sup>(60)</sup>. Identification success was 100 % , without complications.

CEUS was an alternative sonographic method to drop-in robotic ultrasound for in situ renal blood flow mapping after contrast agent injection <sup>(68)</sup>. It allowed occlusion angiography after mapping vasculature and scanning the tumor along with its position and intraparenchymal depth assessment. Tumor identification rate was 100 % <sup>(69)</sup>.

Efficacy of embolization techniques, such as iodized oil TAE and TAE NIRF-ICG, in localizing endophytic tumors was specified in one study <sup>(70-72)</sup>. Mean tumor size was 30mm, identification success rate was 100 % , with no positive margins or recurrences at 12-month follow-up and no need for ultrasonography assistance.

A.R. techniques with real-time 3D to 3D registration were: Hyperaccuracy 3-dimensional reconstruction (HA3D) <sup>(73,74)</sup> and Inverse Realism technique using NVIDIA Quadro DVP hardware <sup>(75)</sup>. Comparing HA3D to 2D IOUS techniques, both showed 100 % identification success rates, but with improved maneuverability, enhanced surgical movement and visualization of other hidden structures such as vessels or calyces for the HA3D arm. HA3D aided in 90% successful selective clamping versus 39 % successful pedicle management in non-HA3D group without positive margins in both arms. 3D to 2D image fusion utilizing vascular pulsation cues for guiding preoperative to intraoperative registration <sup>(76)</sup> was used for occluded structures tracking such as endophytic tumors or vessels occluded by fat during RAPN. IOUS 2D images and 3D reconstructed images integrated in surgical console, but not overlaid to endoscopic view were also described without further numerical data provided. VSP, used reconstructions created preoperatively, and IOUS real-time imaging both projected simultaneously within surgical view <sup>(77)</sup>. Tumor identification rate was 100 % , showing no positive margins or complications. This technique could be helpful in cases with intraparenchymal or hilar tumors accompanying complicated renal vessels <sup>(78)</sup>.

IOUS-tracked embolization coils, were used in an endophytic isoechoic tumor during retroperitoneal RAPN <sup>(79)</sup>. Identification success 100 % , and negative marginal status or complications, might suggest this as a method of choice when dealing with isoechoic intraparenchymal lesions.

### ***Completely endophytic subgroup analysis for RAPN***

Data were extracted from 13 studies (7 retrospective comparative, 3 retrospective single arm, 3 prospective studies) <sup>(51,63,65,12,50,62,64,57,70,80,77,73,81)</sup>. In 366 tumors, identification success rates were 100 % for A.R. (n = 1), 100 % for IOUS (n = 158), 99.08 % for frozen sample IOUS (n = 109), 100 % for TAE NIRF-ICG (n = 10), and 0 % for intravenous (I.V.) NIRF-ICG (n = 7), (t-test, P = .9730). Intraparenchymal growth showed no significant correlation to warm ischemia time <sup>(62)</sup>. Analysis for positive margins in IOUS guided RAPN and A.R. navigation for completely endophytic tumors with or without frozen biopsies had total 95 % CI ; 0.379-3.109, OR 1.086, P = .878, with moderate heterogeneity ( $I^2 = 46.39\%$  , P = .0826) (Figure. 4).

Positive margins using IOUS RAPN for intrarenal versus exophytic tumors had 95%CI; 0.00336-1.221, OR 0.0641. Positive margins with frozen sample IOUS had 95%CI; 1.209-15.835, OR 4.375, for completely endophytic versus mesophytic or exophytic masses in LPN compared to RAPN. Positive margins for A.R. techniques such as HA3D compared to IOUS control group, had 95 % CI ; 0.186-247.067, OR 6.778.

Total 95 % CI ; 0.0917-2.251, OR 0.454, P= .0334 with low heterogeneity ( $I^2 = 0.00\%$  , P = .07645) was estimated for recurrence in frozen sample IOUS RAPN for intrarenal tumors, as other identification techniques showed insufficient data for further analysis. Frozen sample IOUS had 95 % CI ; 0.0299-3.932, OR 0.343 for recurrence after RAPN compared to OPN and 95 % CI ; 0.0673-4.686, OR 0.562 for recurrence after RAPN when comparing intrarenal to mesophytic or exophytic tumors (Figure. 5).

### ***Radiofrequency Ablation***

Data from 14 studies, with 225 endophytic renal masses that underwent Radiofrequency Ablation (RFA), were collected (Table 3). 127 neoplasms underwent percutaneous RFA (PRFA), 55 underwent Laparoscopic RFA (LRFA), and 26 underwent RFA assisted RAPN. Hybrid laparoscopic and robotic RFA assisted partial nephrectomy was described in literature without specific data recorded.

Localization methods described during PRFA were: CT guidance alone or combined with CT guidance under general anesthesia (G.A-CT) and Fiber optic thermal monitoring (FOTM) <sup>(82-85)</sup>, Fluoroscopy CT (F-CT) guidance with embolization coil markers (n = 8) <sup>(86)</sup>, Ultrasound (US)-only guidance (n = 9) <sup>(87)</sup> and iodized oil TAE <sup>(88)</sup>. RFA with GA-CT and FOTM (n = 43) was the only method with 93.48 % technical success rate and



8.7 % recurrence rate compared to 100 % success rate and 0 % recurrence rate of other modalities. Tumor size data were only provided for US RFA, showing mean size 26.9mm. Complication rate 0% was announced for US and F-CT embolization coil methods. TAE was used for difficult-to-detect endophytic tumors, but concise numerical data regarding success rate and surgical outcomes were not provided.

LRFA was facilitated either by IOUS-alone <sup>(85), (89-91)</sup> or combined with visual guidance and FOTM <sup>(92), (93)</sup> or CEUS <sup>(94)</sup> for tumor localization. IOUS-alone technical success rate was 80 % -100 % and recurrence rate was 0 % overall. RFA assisted robotic clamp-less partial nephrectomy for 26 endophytic tumors had 100 % technical success rate and 0 % recurrence rate using IOUS alone <sup>(95)</sup>. Results were inconclusive for IOUS-FOTM and CEUS.

### ***Cryoablation***

Data from 10 studies including 187 endophytic tumors treated with Cryoablation were collected (Table 3). 159 masses underwent with percutaneous Cryoablation (PCA) and 28 were treated with Cryoablation during laparoscopy (LCA). 88 were completely endophytic.

Identification techniques used in PCA were: F-CT only or combined with US (n = 112) <sup>(96-99)</sup> and TAE (n = 29) combined with CT guidance such as iodized oil and absolute ethanol TAE <sup>(100)</sup>, iodized oil and gelatin particles TAE <sup>(101)</sup>, or polyvinyl alcohol particles in iodinated contrast agent TAE <sup>(102)</sup>.

Combined US and intermittent CT imaging during ablation for 76 masses showed 100% technical success rate, complication rates were 10 % -32 % . Recurrence rate was 13 % in one retrospective single arm study with long term follow-up. F-CT only method, had 75 % technical success rate and 12.5 % recurrence rate in a retrospective study including 8 endophytic tumors with mean size 27mm.

Iodized oil and absolute ethanol TAE showed inferior results compared to other TAE techniques, with technical success rate 94.12 % , and 29.4 % recurrence rate, versus 100 % technical success rate and 0 % recurrence rate respectively. Outcomes were comparable despite small study samples.

IOUS was the only identification method described during LCA. A retrospective single arm study <sup>(103)</sup> showed 33.4 % technical success rate, 0 % complication and recurrence rate in mid-term follow-up during LCA for 3 completely endophytic non-visible tumors. Limited data, indicated ultrasonography signage inexpediency

for treating intrarenal tumors. Retrospective comparative studies analysis on CT guided PCA and IOUS guided LCA <sup>(104,105)</sup> showed 100 % technical success and 20 % recurrence rates for both arms, while limitations such as small sample size and restrictions in definitions of technical success, persistent enhancement and recurrence, obscured safe statistical conclusions.

### ***Microwave Ablation***

Data regarding Microwave Ablation (MWA) were collected (Table 3). Yu et al. 2012 <sup>(106)</sup> reviewed intermediate-term outcomes after MWA with US and FOTM sensors for 44 endophytic masses, mean size 18mm. 26 had parenchymal and 18 had endophytic growth pattern with 17.9-19.8 months median-follow up. Parenchymal nodules showed 100 % technique efficacy, and no recurrences. Endophytic masses showed 94.4 % technique efficacy, and 15 % showed recurrence.

Retrospective comparative studies <sup>(107-109)</sup> on CT percutaneous thermal ablation for 165 endophytic masses showed overall 100 % technical success rate for all intervention types. In MWA group, no urothelial injury or Clavien-Dindo II-IV complications occurred.

### ***Irreversible Electroporation***

One study from Diehl et al. <sup>(110)</sup> reported the use of Irreversible Electroporation (IRE) in endophytic tumors, but data were inconclusive (Table 3).

### ***Completely endophytic subgroup analysis for thermal ablation***

Data were extracted from 11 studies (9 retrospective single arm, 1 retrospective comparative, 1 prospective) <sup>(83,84,87,86,93,96,100,101,99,103,106)</sup> including 153 completely endophytic tumors. Localization methods during PRFA were: CT guidance alone or combined with US (n = 18), US-alone (n = 9), and F-CT with embolization coil markers (n = 8). Deep endophytic tumors during LRFA were identified with FOTM IOUS. Identification techniques during PCA were: CT guidance alone or combined with US (n = 77) and iodized oil TAE (n = 12), while IOUS was the only localization modality used during LCA (n = 3). US with FOTM was used for 26 tumors during percutaneous MWA. Total OR for technical success after thermal ablation procedures was 95 % CI ; 0.137-5.167, OR 0.842, P= .853.

We applied separate pooled OR reporting for invasive (Figure 6.) and non-invasive (Figure 7.) localization techniques regarding technical success in ablation procedures, in order to avoid heterogeneous data analysis. Invasive techniques: Iodized TAE in PCA, 95 % CI ; 0.0118-9.39), OR 0.333 and laparoscopic IOUS guidance in PCA, 95 % CI ; 0.000293-0.291, OR 0.00923 both showed less likelihood for technical success, total random effect 95 % CI ; 0.0157-2.060, OR 0.05690, fixed effect 95 % CI ; 0.00799-0.907, OR 0.0851,  $P = .041$ , with significant heterogeneity of data 95 % CI ; 0.00-89.13,  $I^2$  55.26 % . Non-invasive techniques: All non-invasive imaging techniques showed increased likelihood for success with total random effects 95 % CI ; 0.598-13.152, OR 2.804 and low heterogeneity of data 95 % CI ; 0.00- 25.11,  $I^2$  0.00 % . US guidance in percutaneous RFA, 95 % CI ; 0.262- 152.872, OR 6.333 and combined CT and US guidance, especially when performed under FOTM, in MWA : 95 % CI ; 0.137 -91.090, OR 3.533, in PCA: 95 % CI ; 0.118- 47.114, OR 2.361 and PRFA: 95 % CI ; 0.0696- 26.205, OR 1.35, showed increased likelihood for success.

Comparison between thermal ablation methods showed that endophytic growth pattern attributed to hematoma formation with Mean Relative Risk (RR) 95 % CI ; 0.90-1.51, RR 1.15 and to residual disease with Mean 95 % CI ; 1.10-1.87, RR 1.30 <sup>(107-109)</sup>. Overall estimated cumulative incidence of recurrence was 95 % CI ; 1-19, 5 % , at 3 years and 95 % CI ; 4-27, 10 % at 5 years for PCA using combined CT and US guidance for completely endophytic tumors <sup>(96)</sup> . Wingo et. al.2008 <sup>(93)</sup>, contrariwise, failed to predict increased risk for recurrence due to endophytic location ( $\chi^2 = .81 < 5.99$ ) for CT-FOTM PRFA or IOUS LRFA.

### ***High Intensity Focused Ultrasound***

Ritchie et al. <sup>(111)</sup> evaluated 5 entirely endophytic tumors, mean size 20,4mm treated with High Intensity Focused Ultrasound (HIFU). US was used for tumor localization, surgical planning and real time evaluation. All were successfully identified. Technical success rate was 20 % . No major complications occurred. Recurrence rate was 25 % in a mean 36-month follow-up.

## **Discussion**

Evidence on excision techniques showed that IOUS was widely applied identification method, with high identification rates, and recurrence rates up to 1.6 % in follow up period up to 60 months. Positive margin rates were 1.96-12.5 % in LPN and 0-6.1 % in RAPN, while complication rates varied from 0 % in LPN to 0-21.8 % in RAPN. Kaczmarek et al.2013 <sup>(54)</sup> showed similar efficacy between Laparoscopic and Robotic IOUS probes,

Robotic group though, excelled in autonomy, maneuverability, cost effectiveness and practicality when depicting challenging tumor angles. Frozen sample IOUS during RAPN, showed increased complications, without improving positive margin or recurrence rates; making questionable whether it should be performed. LDU or CEUS showed insufficient data regarding tumor tracking, but aided in identifying hidden vasculature, defining safe excisional margins or contact with the collecting system. DSCT combined high identification success rate with efficient tumor feeding artery orientation.

A.R. was useful in identification especially within robotic setting. Overlapped 3D onto real- time endoscopic image, enhanced anatomical structures <sup>(112)</sup>. Despite high identification success rates, data were inconclusive to support superiority over conventional techniques. Findings compatible with international literature <sup>(113,114)</sup>. Only HA3D showed superiority compared to IOUS during RAPN regarding surgical autonomy, and selective artery clamping.

Isoechoic intraparenchymal mass tracking was achieved using embolization coils during RAPN. Further studies are needed to confirm whether embolization coil or hook wire techniques could be the gold standard for such tumors.

Unlike TAE NIRF-ICG, I.V. NIRF-ICG was contraindicated for endophytic tumors <sup>(115,40)</sup>. Studies <sup>(80,81)</sup> showed no identification success. The only utility for intraparenchymal lesions, was tumor delineation once surrounding normal parenchyma was first incised <sup>(116-119)</sup>.

Regarding excision methods for completely endophytic tumors, identification success rates were high, regardless of identification technique, both for LPN and RAPN. Positive margins showed 40% less likelihood in IOUS guided LPN compared to RAPN and significantly decreased odds for IOUS guided LPN or RAPN for totally intraparenchymal tumors compared to masses with exophytic component. Odds for positive margins were increased in A.R. techniques compared to IOUS during laparoscopic or robotic procedures for intrarenal masses. Chances for recurrence were in favor of IOUS LPN compared to RAPN, LCA or laparoscopic radical nephrectomy and increased odds for recurrence were found during laparoscopy for intraparenchymal versus exophytic masses. Frozen sample IOUS showed increased likelihood for positive margins in intrarenal compared to exophytic tumors and 45% less likelihood for recurrence of parenchymal masses compared to mesophytic or other exophytic lesions.

Evidence on ablation procedures suggest that, CT was preferred to US during all thermal ablation procedures due to improved anatomic resolution, ancillary maneuver permeability and periprocedural complication evaluation <sup>(109)</sup>. CT guided PRFA had technical success rate 93.48 % -100 % and recurrence rate 0-8.7 % in 2-year follow-up. G.A aided in better targeting and minimizing complications risk. Wingo et al.2008 <sup>(93)</sup> showed that FOTM RFA, improved success rate. Gupta et al.2009 <sup>(82)</sup> showed that OR, an endophytic lesion compared to non-endophytic to be incompletely treated, was 95 % CI ; 0.65-24.8, OR 4.0. RR of developing any recurrence for endophytic lesions compared to non-endophytic was 95 % CI ; 0.6-11.7, RR 2.6, P = .20. Endophytic tumors were more resistant to ablation because of the “heat sink” effect caused by blood vessels surrounding the tumor.

Endophytic central masses had the highest risk for recurrence (Hazard Ratio HR, 6.3; P = .016). Matsumoto et al.2005. <sup>(120)</sup> stated that, endophytic lesions, hardly localized during open partial nephrectomy and technically challenging for LPN, were easily targeted and ablated with CT-guided RFA. Pietryga et al.2012 <sup>(86)</sup> showed that use of marker coils in poorly visualized tumors, such as intraparenchymal and isoechoic lesions, facilitated CT PRFA, by 58 % reduction in CT fluoroscopy time, showing equivalent technical outcomes with non-coil group. TAE as add-on to PRFA for difficult-to-detect endophytic tumors, reviewed by Sommer et al.2017 <sup>(88)</sup>, showed that residual post ablation positive margins were more common for endophytic tumors.

IOUS LRFA, showed technical success 80-100%. Yang et al.2014 <sup>(94)</sup> showed that CEUS, improved tumor outline visibility prior to ablation, allowed enhancement status evaluation after ablation, required no warm ischemia and allowed increased parenchymal preservation.

CT PCA showed technical success 75 % , reaching 100 % when combined with US. Recurrence rate was approximately 13 % in short-term follow-up, and complication rate was 10-32 %. TAE PCA, technical success rate was comparable (94.12 % to 100 % ) but with higher percentage for recurrences (29.4 % ). Harmon et al.2018 <sup>(102)</sup> showed that pre ablation adjuvant embolization allowed better tumor demarcation, reduced cryoneedles needed and minimized procedural cost and complications.

The “poor visualization phenomenon” concerning intraparenchymal or partly endophytic renal masses in unenhanced CT was a factor compromising PCA success. Therefore, Kajiwar et al.2020 <sup>(101)</sup> proposed a five-tier visualization score based on Hounsfield units. Mean visualization score, solely for endophytic and parenchymal

tumors, after TAE PCA was 4, representing a tumor margin visibility 75-90 % . Data on IOUS LCA, showed technical success 33.4 % , probably due to ultrasonography signage inexpediency <sup>(103)</sup>. Multivariate analysis revealed that only endophytic status is a predictor of failure. Derweesh et al.2008 <sup>(105)</sup> compared LCA to PCA for endophytic tumors and showed that they had significant association with tumor persistence. Nisbet et al. 2009 <sup>(121)</sup> proposed a decision tree on whether to perform IOUS LCA or LPN for small renal masses. Endophytic tumors were predicted to have better results when treated with LCA.

Results on completely endophytic subgroup for ablation procedures, showed that non-invasive imaging techniques had increased likelihood of success. CT PRFA had slightly increased odds for technical success between totally intrarenal and endophytic tumors (95 % CI ; 0.0696- 26.205, OR 1.351). Technical success during US PRFA was also in favor of intraparenchymal masses. Combined CT and US PCA, favored success over completely endophytic lesions compared to other endophytic tumors. US MWA with FOTM, increased likelihood of success when applied to intrarenal masses compared to endophytic. Contrariwise, invasive techniques showed less likelihood for success. TAE PCA showed 33 % less likelihood of success for intrarenal masses compared to masses with exophytic component. Chances of success for completely endophytic tumors were significantly lower compared to masses with exophytic component during IOUS LCA (95 % CI ; 0.000293-0.291, OR 0.00923). Data on recurrence after ablation were contradictory and therefore inconclusive.

Our limitations were 1) Study selection bias from English language restriction: Additional database search resulted in 6 studies eligible for further evaluation according to abstract, written in Russian, Spanish, French and Hebrew. As authors were incapable of translating, we avoided including non-English literature due to bias of misinterpretation. 2) Further databases could have been searched, such as Scopus, which was not searched due to limited access. 3) Serious uncontrolled confounding bias due to unmeasured confounders. 4) Sparse data bias: unrealistic huge pooled OR estimates and confidence limits, observed in subgroup analysis, suggest that sparse data is an important source of bias. 5) Bias deriving from study design: No randomized controlled studies and limited number of prospective studies were included (6 comparative, 5 single arm studies and 1 multi-institutional), the majority were retrospective, making data extraction strenuous due to ambiguous reporting quality. 6) Missing data within studies: Data were partially missing or inconclusive in 58 studies, while 19 had complete data for extraction. 7) Heterogeneity in terminology: Variance in definitions of terms was a major drawback. The term endophytic described a variety of masses, ranging from totally intraparenchymal to masses protruding up to 50%

from capsule. Other definitions such as technical success rate, tumor response rate and recurrence, were diverse among studies resulting in bias during interpretation of outcomes, although Goldberg et al.2003<sup>(122)</sup> proposed a protocol for Standardization of Terms and Reporting Criteria for image guided ablation. 8) Small study samples. Low level of evidence, inconsistent reporting of data, bias in study design or subgroup analysis, small samples and heterogeneity of definitions led us to perform a narrative systematic review instead of meta-analysis.

## **Conclusion**

IOUS in LPN and RAPN was adequately evaluated method for tumor localization with high identification rates and acceptable oncologic outcomes. A.R., although showing increased surgical maneuverability and autonomy, showed no superiority regarding identification success, positive margins and recurrences. I.V NIRF-ICG, was not an appropriate option for successful endophytic tumor tracking.

CT alone or combined with FOTM and US, showed increased technical success for endophytic and intraparenchymal tumors during thermal ablation. US alone during LCA, had discouraging results regarding technical success. Limited evidence on isoechoic endophytic masses, suggest that more invasive localization methods such as hook-wire or embolization coil techniques, might rise as method of choice for such tumors.

## **References**

1. Ljungberg B, Albiges L, Abu-Ghanem Y, et al. European Association of Urology Guidelines on Renal Cell Carcinoma: The 2019 Update. *Eur. Urol.* 2019; 75:799–810.
2. Husain FZ, Badani KK, Sfakianos JP, Mehrazin R. Emerging surgical treatments for renal cell carcinoma. *Future Oncol.* 2016; 12:921–929.
3. Gill IS (2003) Minimally invasive nephron-sparing surgery. *Urol. Clin. North Am.* 30:551–579.
4. Withington J, Neves JB, Barod R Surgical and Minimally Invasive Therapies for the Management of the Small Renal Mass. *Curr. Urol. Rep.* 2017; 18:1–9.
5. Singla N, Gahan J. New technologies in tumor ablation. *Curr Opin Urol.* 2016; 26:248–253.

6. Prins FM, Kerkmeijer LGW, Pronk AA, et al. Renal Cell Carcinoma: Alternative Nephron-Sparing Treatment Options for Small Renal Masses, a Systematic Review. *J. Endourol.* 2017; 31:963–975.
7. Kutikov A, Uzzo RG. The R.E.N.A.L. Nephrometry Score: A Comprehensive Standardized System for Quantitating Renal Tumor Size, Location and Depth. *J. Urol.* 2009; 182:844–853.
8. Jose M (2009) PICO Worksheet and Search Strategy Name. 2014
9. Moher D, Liberati A, Tetzlaff J, Altman DG. Preferred reporting items for systematic reviews and meta-analyses: the PRISMA statement. *J.Clin. Epidemiol.* 2009; 62:1006–1012.
10. McGuinness LA, Higgins JPT. Risk-of-bias VISualization (robvis): An R package and Shiny web app for visualizing risk-of-bias assessments. *Res. Synth. Methods.* 2021; 12:55–61.
11. Sterne JAC, Hernán MA, Reeves BC, et al. ROBINS-I : a tool for assessing risk of bias in non-randomised studies of interventions (“ Risk Of Bias In Non-randomised tool for evaluating risk of bias in. 4–10. *BMJ* 2016;355:i4919.
12. Gu L, Liu K, Shen D, et al. Comparison of robot-assisted and laparoscopic partial nephrectomy for completely endophytic renal tumors : a high- volume center experience. 1–25. *J. Endourol.* 2019; 34, 581-587.
13. Qin B, Hu H, Lu Y, et al. Intraoperative ultrasonography in laparoscopic partial nephrectomy for intrarenal tumors. *PLoS ONE.* 2018; 13:1–9.
14. Nadu A, Goldberg H, Lubin M, Baniel J. Laparoscopic partial nephrectomy ( LPN ) for totally intrarenal tumours. *BJUI.* 2013; 112. E82-E86.
15. Chung BI, Lee UJ, Kamoi K, et al. Laparoscopic partial nephrectomy for completely intraparenchymal tumors. *J. Urol.* 2011; 186:2182–2187.
16. Pierro GB Di, Tartaglia N, Aresu L, Polara A. Laparoscopic partial nephrectomy for endophytic hilar tumors : feasibility and outcomes. *Eur J Surg Oncol.* 2014; 40:769–774.
17. Gao Y, Chen L, Ning Y, et al. Hydro-Jet-assisted laparoscopic partial nephrectomy with no renal arterial clamping: A preliminary study in a single center. *Int Urol Nephrol.* 2014; 46:1289–1293.



18. Engel JD, Williams SB. Unclamped hand-assisted laparoscopic partial nephrectomy for predominantly endophytic renal tumors. *Urol. J.* 2013; 10:767–773.
19. Venkatesh R, Weld K, Ames CD, et al. Laparoscopic partial nephrectomy for renal masses: Effect of tumor location. *Urology.* 2006; 67:1169–1174.
20. Fazio LM, Downey D, Ngan CY, et al. Intraoperative laparoscopic renal ultrasonography: Use in advanced laparoscopic renal surgery. *Urology.* 2006; 68:723–727.
21. Shikanov S, Lifshitz DA, Deklaj T, et al. Laparoscopic partial nephrectomy for technically challenging tumours. *BJUI.* 2010; 106:91–94.
22. Lee SY, Choi JD, Seo S II. Current status of partial nephrectomy for renal mass. *Korean J. Urol.* 2011; 52:301–309.
23. Yang F, Liu S, Mou L, et al. Application of intraoperative ultrasonography in retroperitoneal laparoscopic partial nephrectomy: A single-center experience of recent 199 cases. *Endosc. Ultrasound.* 2019; 8:118–124.
24. Sun MRM, Wagner AA, San Francisco IF, et al. Need for intraoperative ultrasound and surgical recommendation for partial nephrectomy: Correlation with tumor imaging features and urologist practice patterns. *Ultrasound Q.* 2012; 28:21–27.
25. Kang N, Niu Y, Zhang J, et al. Intraoperative ultrasonography: A useful tool in retrolaparoscopic nephron-sparing surgery. *Urol. Int.* 2012; 88:338–342.
26. Belldegrin A, Kim H, Landman J, Wolf JS. Intraoperative ultrasonography in urologic oncology. *Urol. Oncol.: Semin. Orig. Investig.* 2004; 22:153–155.
27. Secil M, Elibol C, Aslan G, et al. Role of intraoperative US in the decision for radical or partial nephrectomy. *International Braz J Urol.* 2011; 37:277.
28. Aron M TB. Laparoscopic partial nephrectomy: Newer trends. *Indian J Urol.* 2009; 25:516–22.
29. Anderson JK, Shingleton WB, Cadeddu JA. Imaging Associated with Percutaneous and Intraoperative Management of Renal Tumors. *Urol. Clin. North Am.* 2006; 33:339–352.

30. Shao P, Tang L, Li P, et al. Precise segmental renal artery clamping under the guidance of dual-source computed tomography angiography during laparoscopic partial nephrectomy. *Eur. Urol.* 2012; 62:1001–1008.
31. Fan G, Li J, Li M, et al. Three-Dimensional Physical Model-Assisted Planning and Navigation for Laparoscopic Partial Nephrectomy in Patients with Endophytic Renal Tumors. *Sci. Rep.* 2018; 8:4–9.
32. Mandoorah Q, Rozet F, Muttin F, et al. Hook Wire Placement Facilitates Laparoscopic Excision of Endophytic Renal Tumor in Partial Nephrectomy. *J. Endourol. Case Rep.* 2018; 4:163–165.
33. Kouriefs C, Georgiades F, Michaelides M, et al. Percutaneous hook wire assistance during laparoscopic excision of an intrarenal mass. *Ann R Coll Surg Engl.* 2019; 101: E136–E138.
34. Bouvier A, Besnier L, Paisant A, et al. Blue dye embolization of renal tumor: A new technique to improve tumor localization during laparoscopic partial nephrectomy. *J Laparoendosc Adv Surg Tech A.* 2020; 30:299–303.
35. Hughes-Hallett A, Mayer EK, Marcus HJ, et al. Augmented reality partial nephrectomy: Examining the current status and future perspectives. *Urology.* 2014; 83:266–273.
36. Mitchell CR, Herrell SD. Image-Guided Surgery and Emerging Molecular Imaging: Advances to Complement Minimally Invasive Surgery. *Urol. Clin. North Am.* 2014; 41:567–580.
37. Simpfendorfer T, Gasch C, Hatiboglu G, et al. Intraoperative Computed Tomography Imaging for Navigated Laparoscopic Renal Surgery: First Clinical Experience. *J. Endourol.* 2016; 30:1105–1111.
38. Teber D, Guven S, Simpfendorfer T, et al. Augmented Reality: A New Tool To Improve Surgical Accuracy during Laparoscopic Partial Nephrectomy? Preliminary In Vitro and In Vivo Results. *Eur. Urol.* 2009; 56:332–338.
39. Rassweiler J, Rassweiler MC, Müller M, et al. Surgical navigation in urology: European perspective. *Curr Opin Urol.* 2014; 24:81–97.

40. Hekman MCH, Rijpkema M, Langenhuijsen JF, et al. Intraoperative Imaging Techniques to Support Complete Tumor Resection in Partial Nephrectomy. *Eur. Urol. Focus.* 2018; 4:960–968.
41. Chen Y, Li H, Wu D, et al. Surgical planning and manual image fusion based on 3D model facilitate laparoscopic partial nephrectomy for intrarenal tumors. *World J. Urol.* 2014; 32:1493–1499.
42. Wang J, Lu Y, Wu G, et al. The role of three-dimensional reconstruction in laparoscopic partial nephrectomy for complex renal tumors. *World J. Surg. Oncol.* 2019; 17:1–7.
43. Zhang S, Yang G, Tang L, et al. Application of a Functional 3-dimensional Perfusion Model in Laparoscopic Partial Nephrectomy With Precise Segmental Renal Artery Clamping. *Urology.* 2019; 125:98–103.
44. Wang D, Zhang B, Yuan X, et al. Preoperative planning and real-time assisted navigation by three-dimensional individual digital model in partial nephrectomy with three-dimensional laparoscopic system. *Int. J. Comput. Assist. Radiol. Surg.* 2015; 10:1461–1468.
45. Hernández JAB, Donoso CV, Martinez-Sarmiento M, et al. Application of the Radio-Guided Occult Lesion Localization Technique for Renal Lumpectomy: From the Laboratory to the Patient. *Clin. Nucl. Med.* 2017; 42: e467–e468.
46. Perez-Ardavin J, Sanchez-Gonzalez JV, Martinez-Sarmiento M, et al. Surgical Treatment of Completely Endophytic Renal Tumor: a Systematic Review. *Curr. Urol. Rep.* 2019; 20:3.
47. Arora S, Rogers C. Partial Nephrectomy in Central Renal Tumors. *J. Endourol.* 2018; 32: S63–S67.
48. Di Cosmo G, Verzotti E, Silvestri T, et al. Intraoperative ultrasound in robot-assisted partial nephrectomy: State of the art. *Arch Ital Urol Androl.* 2018; 90:195–198.
49. Gunelli R, Fiori M, Salaris C, et al. The role of intraoperative ultrasound in small renal mass robotic enucleation. *Arch Ital Urol Androl.* 2016; 88:311–313.
50. Kara O, Maurice MJ, Malkoc E, et al. Comparison of robot-assisted and open partial nephrectomy for completely endophytic renal tumours: a single centre experience. *BJUI.* 2016; 118:946–951.

51. Curtiss KM, Ball MW, Gorin MA, et al. Perioperative outcomes of robotic partial nephrectomy for intrarenal tumors. *J. Endourol.* 2015; 29:293–296.
52. Boylu U, Basatac C, Yildirim U, et al. Comparison of surgical, functional, and oncological outcomes of open and robot-assisted partial nephrectomy. *J. Minimal Access Surg.* 2015; 11:72–77.
53. Autorino R, Khalifeh A, Laydner H, et al. Robot-assisted partial nephrectomy (RAPN) for completely endophytic renal masses: A single institution experience. *BJUI.* 2014; 113:762–768.
54. Kaczmarek BF, Sukumar S, Kumar RK, et al. Comparison of robotic and laparoscopic ultrasound probes for robotic partial nephrectomy. *J. Endourol.* 2013; 27:1137–1140.
55. Kim EH, Tanagho YS, Sandhu GS, et al. Off-clamp robot-assisted partial nephrectomy for complex renal tumors. *J. Endourol.* 2012; 26:1177–1182.
56. Kaczmarek BF, Sukumar S, Petros F, et al. Robotic ultrasound probe for tumor identification in robotic partial nephrectomy: Initial series and outcomes. *Int. J. Urol.* 2013; 20:172–176.
57. White MA, Haber GP, Autorino R, et al. Outcomes of robotic partial nephrectomy for renal masses with nephrometry score of  $\geq 7$ . *Urology.* 2011; 7:809–813.
58. Gong Y, Du C, Josephson DY, et al. Four-arm robotic partial nephrectomy for complex renal cell carcinoma. *World J. Urol.* 2010; 28:111–115.
59. Ho H, Schwentner C, Neururer R, et al. Robotic-assisted laparoscopic partial nephrectomy: Surgical technique and clinical outcomes at 1 year. *BJUI.* 2009; 103:663–668.
60. Rogers CG, Singh A, Blatt AM, et al. Robotic Partial Nephrectomy for Complex Renal Tumors: Surgical Technique. *Eur. Urol.* 2008; 53:514–523.
61. Hyams ES, Perlmutter M, Stifelman MD. A prospective evaluation of the utility of laparoscopic doppler technology during minimally invasive partial nephrectomy. *Urology.* 2011; 77:617–620.
62. Shiroki R, Fukami N, Fukaya K, et al. Robot-assisted partial nephrectomy: Superiority over laparoscopic partial nephrectomy. *Int. J. Urol.* 2016; 23:122–131.

63. Abdel Raheem A, Chang KD, Alenzi MJ, et al. Robot-assisted partial nephrectomy for totally endophytic renal tumors: Step by step standardized surgical technique and long-term outcomes with a median 59-month follow-up. *J Laparoendosc Adv SurgTech A*. 2019; 29:1–11.
64. Komninos C, Shin TY, Tuliao P, et al. Robotic partial nephrectomy for completely endophytic renal tumors: Complications and functional and oncologic outcomes during a 4-year median period of follow-up. *Urology*. 2014; 84:1367–1373.
65. Harke NN, Mandel P, Witt JH, et al. Are there limits of robotic partial nephrectomy? TRIFECTA outcomes of open and robotic partial nephrectomy for completely endophytic renal tumors. *J. Surg. Oncol*. 2018; 118:206–211.
66. Tiryaki S, Turna B, Kışmalı E, Ulman İ. Robotic partial nephrectomy in a child with kidney tumor. *Turk. J. Urol*. 2019; 45: S188–S191.
67. Ceccarelli G, Codacci-Pisanelli M, Patriti A, et al. Robotic-assisted transperitoneal nephron-sparing surgery for small renal masses with associated surgical procedures: Surgical technique and preliminary experience. *Updates Surg*. 2013; 65:183–190.
68. Alenezi A, Motiwala A, Eves S, et al. Robotic assisted laparoscopic partial nephrectomy using contrast-enhanced ultrasound scan to map renal blood flow. *Int J Med Robotics Comput Assist Surg*. 2016; 13, e1738
69. Rao AR, Gray R, Mayer E, et al. Occlusion angiography using intraoperative contrast-enhanced ultrasound scan (CEUS): A novel technique demonstrating segmental renal blood supply to assist zero-ischaemia robot-assisted partial nephrectomy. *Eur. Urol*. 2013; 63:913–919.
70. Simone G, Tuderti G, Anceschi U, et al. “Ride the Green Light”: Indocyanine Green–marked Off-clamp Robotic Partial Nephrectomy for Totally Endophytic Renal Masses. *Eur. Urol*. 2019; 75:1008–1014.
71. Veccia A, Antonelli A, Hampton LJ, et al. Near-infrared Fluorescence Imaging with Indocyanine Green in Robot-assisted Partial Nephrectomy: Pooled Analysis of Comparative Studies. *Eur. Urol. Focus*. 2020; 6:505–512.

72. Cacciamani GE, Shakir A, Tafuri A, et al. Best practices in near-infrared fluorescence imaging with indocyanine green (NIRF/ICG)-guided robotic urologic surgery: a systematic review-based expert consensus. *World J. Urol.* 2020; 38:883–896.
73. Porpiglia F, Fiori C, Checcucci E, et al. Hyperaccuracy Three-dimensional Reconstruction Is Able to Maximize the Efficacy of Selective Clamping During Robot-assisted Partial Nephrectomy for Complex Renal Masses. *Eur. Urol.* 2018; 74:651–660.
74. Porpiglia F, Checcucci E, Amparore D, et al. Three-dimensional Augmented Reality Robot-assisted Partial Nephrectomy in Case of Complex Tumours (PADUA  $\geq 10$ ): A New Intraoperative Tool Overcoming the Ultrasound Guidance. *Eur. Urol.* 2020; 78:229–238.
75. Pratt P, Mayer E, Vale J, et al. An effective visualisation and registration system for image-guided robotic partial nephrectomy. *J. Robot. Surg.* 2012; 6:23–31.
76. Nosrati MS, Amir-Khalili A, Peyrat JM, et al. Endoscopic scene labelling and augmentation using intraoperative pulsatile motion and colour appearance cues with preoperative anatomical priors. *Int. J. Comput. Assist. Radiol. Surg.* 2016; 11:1409–1418.
77. Lasser MS, Doscher M, Keehn A, et al. Virtual surgical planning: A novel aid to robot-assisted laparoscopic partial nephrectomy. *J. Endourol.* 2012; 26:1372–1379.
78. Furukawa J, Miyake H, Tanaka K, et al. Console-integrated real-time three-dimensional image overlay navigation for robot-assisted partial nephrectomy with selective arterial clamping: early single-centre experience with 17 cases. *Int J Med Robotics Comput Assist Surg.* 2014; 10:385–390.
79. Reeves JJ, Forauer A, Seigne JD, Hyams ES. Image-Guided Embolization Coil Placement for Identification of an Endophytic, Isoechoic Renal Mass During Robotic Partial Nephrectomy. *J. Endourol. Case Rep.* 2015; 1:59–61.
80. Krane LS, Manny TB, Hemal AK. Is near infrared fluorescence imaging using indocyanine green dye useful in robotic partial nephrectomy: A prospective comparative study of 94 patients. *Urology.* 2012; 80:110–118.

81. Angell JE, Khemees TA, Abaza R. Optimization of near infrared fluorescence tumor localization during robotic partial nephrectomy. *J. Urol.* 2013; 190:1668–1673.
82. Amit Gupta, Jay D. Raman, et al. General Anesthesia and Contrast-Enhanced Computed Tomography to Optimize Renal Percutaneous Radiofrequency Ablation: Multi-Institutional Intermediate-Term Results. *J. Endourol.* 2009; 23:1099–1105.
83. Gervais DA, McGovern FJ, Arellano RS, et al. Radiofrequency ablation of renal cell carcinoma: Part I, indications, results, and role in patient management over a 6-year period and ablation of 100 tumors. *Am J Roentgenol.* 2005; 185:64–71.
84. Farrell MA, Charboneau WJ, DiMarco DS, et al. Imaging-guided radiofrequency ablation of solid renal tumors. *Am J Roentgenol.* 2003; 180:1509–1513.
85. Matsumoto ED, Watumull L, Johnson DB, et al. The radiographic evolution of radio frequency ablated renal tumors. *J. Urol.* 2004; 172:45–48.
86. Pietryga JA, Beland MD, Dupuy DE, Mayo-Smith WW. Placement of marker coils at biopsy: Usefulness in the localization of poorly visualized renal neoplasms for subsequent CT-guided radiofrequency ablation. *Radiology.* 2012; 263:555–561.
87. Veltri A, De Fazio G, Malfitana V, et al. Percutaneous US-guided RF thermal ablation for malignant renal tumors: Preliminary results in 13 patients. *Eur. Radiol.* 2004; 14:2303–2310.
88. Sommer CM, Pallwein-Prettner L, Vollherbst DF, et al. Transarterial embolization (TAE) as add-on to percutaneous radiofrequency ablation (RFA) for the treatment of renal tumors: Review of the literature, overview of state-of-the-art embolization materials and further perspective of advanced image-guided tumor. *Eur. J. Radiol.* 2017; 86:143–162.
89. Jacomides L, Ogan K, Watumull L, Cadeddu JA. Laparoscopic application of radio frequency energy enables in situ renal tumor ablation and partial nephrectomy. *J. Urol.* 2003; 169:49–53.
90. Zeltser IS, Moonat S, Park S, et al. Intermediate-term prospective results of radiofrequency-assisted laparoscopic partial nephrectomy: A non-ischaemic coagulative technique. *BJUI.* 2008; 101:36–38.

91. Nadler RB, Perry KT, Smith ND. Hybrid Laparoscopic and Robotic Ultrasound-guided Radiofrequency Ablation-assisted Clampless Partial Nephrectomy. *Urology*. 2009; 74:202–205.
92. Young EE, Castle SM, Gorbatiy V, Leveillee RJ. Comparison of safety, renal function outcomes and efficacy of laparoscopic and percutaneous radio frequency ablation of renal masses. *J. Urol*. 2012; 187:1177–1182.
93. Wingo MS, Leveillee RJ. Central and deep renal tumors can be effectively ablated: Radiofrequency ablation outcomes with fiberoptic peripheral temperature monitoring. *J. Endourol*. 2008; 22:1261–1267.
94. Yang R, Lian H, Zhang G, et al. Laparoscopic radiofrequency ablation with intraoperative contrast-enhanced ultrasonography for T1bN0M0 renal tumors: Initial functional and oncologic outcomes. *J. Endourol*. 2014; 28:4–9.
95. Wu SD, Viprakasit DP, Cashy J, et al. Radiofrequency ablation-assisted robotic laparoscopic partial nephrectomy without renal hilar vessel clamping versus laparoscopic partial nephrectomy: A comparison of perioperative outcomes. *J. Endourol*. 2010; 24:385–391.
96. Murray CA, Welch BT, Schmit GD, et al. Safety and Efficacy of Percutaneous Image-guided Cryoablation of Completely Endophytic Renal Masses. *Urology*. 2019; 133:151–156.
97. Azevedo AAP, Rahal A, Falsarella PM, et al. Image-guided percutaneous renal cryoablation: Five years experience, results and follow-up. *Eur. J. Radiol*. 2018; 100:14–22.
98. Permpongkosol S, Link RE, Kavoussi LR, Solomon SB. Percutaneous Computerized Tomography Guided Cryoablation for Localized Renal Cell Carcinoma: Factors Influencing Success. *J. Urol*. 2006; 176:1963–1968.
99. Atwell TD, Farrell MA, Leibovich BC, et al. Percutaneous Renal Cryoablation: Experience Treating 115 Tumors. *J. Urol*. 2008; 179:2136–2141.
100. Michimoto K, Shimizu K, Kameoka Y, et al. Transcatheter Arterial Embolization with a Mixture of Absolute Ethanol and Iodized Oil for Poorly Visualized Endophytic Renal Masses Prior to CT-Guided Percutaneous Cryoablation. *Cardiovasc Intervent Radiol*. 2016; 39:1589–1594.



101. Kajiwara K, Yoshimatsu R, Nishimori M, et al. Efficacy of arterial infusion of iodized oil on CT-guided cryoablation for renal cell carcinoma. *Minim Invasive Ther Allied Technol.* 2020; 0:1–7.
102. Harmon TS, Matteo J, Meyer TE, Kee-Sampson J. Pre-cryoablation Embolization of Renal Tumors: Decreasing Probes and Saving Loads. *Cureus.* 2018; 10:.
103. Wright AD, Turk TMT, Nagar MS, et al. Endophytic lesions: A predictor of failure in laparoscopic renal cryoablation. *J. Endourol.* 2007; 21:1493–1496.
104. Adam C. Mues, Zhamshid Okhunov, Georgios Haramis, H. D’Agostino Bruce W. Shingleton JL. Comparison of Percutaneous and Laparoscopic Renal Cryoablation for Small (<3.0 cm) Renal Masses. *J. Endourol.* 2010; 24:1097–1100.
105. Derweesh IH, Malcolm JB, Diblasio CJ, et al. Single center comparison of laparoscopic cryoablation and CT-guided percutaneous cryoablation for renal tumors. *J. Endourol.* 2008; 22:2461–2467.
106. Yu J, Liang P, Yu XL, et al. US-guided percutaneous microwave ablation of renal cell carcinoma: Intermediate-term results. *Radiology.* 2012; 263:900–908.
107. Zhou W, Uppot RN, Feldman AS, Arellano RS. Percutaneous image-guided thermal ablation for multifocal renal cell carcinoma: 10-year experience at a single center. *Am J Roentgenol.* 2017; 209:733–739.
108. Zhou W, Arellano RS. Thermal Ablation of T1c Renal Cell Carcinoma: A Comparative Assessment of Technical Performance, Procedural Outcome, and Safety of Microwave Ablation, Radiofrequency Ablation, and Cryoablation. *J Vasc Interv Radiol.* 2018; 29:943–951.
109. Zhou W, Herwald SE, McCarthy C, et al. Radiofrequency Ablation, Cryoablation, and Microwave Ablation for T1a Renal Cell Carcinoma: A Comparative Evaluation of Therapeutic and Renal Function Outcomes. *J Vasc Interv Radiol.* 2019; 30:1035–1042.
110. Diehl SJ, Rathmann N, Kostrzewa M, et al. Irreversible Electroporation for Surgical Renal Masses in Solitary Kidneys: Short-Term Interventional and Functional Outcome. *J Vasc Interv Radiol.* 2016; 27:1407–1413.

111. Ritchie RW, Leslie T, Phillips R, et al. Extracorporeal high intensity focused ultrasound for renal tumours: A 3-year follow-up. *BJUI*. 2010; 106:1004–1009.
112. Checcucci E, De Cillis S, Porpiglia F. 3D-printed models and virtual reality as new tools for image-guided robot-assisted nephron-sparing surgery: A systematic review of the newest evidences. *Curr Opin Urol*. 2020; 30:55–64.
113. Bertolo R, Hung A, Porpiglia F, et al. Systematic review of augmented reality in urological interventions: the evidences of an impact on surgical outcomes are yet to come. *World J. Urol*. 2020; 38:2167–2176.
114. Kim DK, Komninos C, Kim L, Rha KH. Robot-assisted Partial Nephrectomy for Endophytic Tumors. *Curr. Urol. Rep*. 2015; 16:1–7.
115. Hemal AK, Golijanin D. Does infrared imaging improve partial nephrectomy for renal cell carcinoma? *J. Urol*. 2012; 188:1078–1080.
116. Tobis S, Knopf J, Silvers C, et al. Near infrared fluorescence imaging with robotic assisted laparoscopic partial nephrectomy: Initial clinical experience for renal cortical tumors. *J. Urol*. 2011; 186:47–52.
117. Tobis S, Knopf JK, Silvers C, et al. Robot-assisted and laparoscopic partial nephrectomy with near infrared fluorescence imaging. *J. Endourol*. 2012; 26:797–802.
118. Klaassen Z, Li Q, Madi R, Terris MK. The role of indocyanine green for robotic partial nephrectomy: Early results, limitations and future directions. *Robotics*. 2014; 3:281–288.
119. Autorino R, Zargar H, White WM, et al. Current applications of near-infrared fluorescence imaging in robotic urologic surgery: A systematic review and critical analysis of the literature. *Urology*. 2014; 84:751–759.
120. Matsumoto ED, Johnson DB, Ogan K, et al. Short-term efficacy of temperature-based radiofrequency ablation of small renal tumors. *Urology*. 2005; 65:877–881.
121. Nisbet AA, Rieder JM, Tran VQ, et al. Decision tree for laparoscopic partial nephrectomy versus laparoscopic renal cryoablation for small renal masses. *J. Endourol*. 2009; 23:431–437.

122. Goldberg SN, Charboneau JW, Dodd GD, et al. Image-guided tumor ablation: Proposal for standardization of terms and reporting criteria. *Radiology*. 2003; 228:335–345.

## Appendix A

Database	Search String	Filters	Results
PubMed	<p><b>#1:</b> (((((((renal tumor) OR (renal mass)) OR (renal lesion)) OR (renal cancer)) OR (kidney tumor)) OR (kidney mass)) OR (kidney lesion)) OR (kidney cancer) <b>Filters:</b> English. <b>Results:223,715</b></p> <p><b>AND</b></p> <p><b>#2:</b> (((endophytic) OR (intraparenchymal)) OR (intrarenal)) OR (parenchymal) <b>Filters:</b> English. <b>Results: 51,847</b></p> <p><b>AND</b></p> <p><b>#3:</b> (((((minimal invasive) OR (laparoscopic)) OR (3D laparoscopic)) OR (robotic)) OR (robotic assisted)) OR (ablation)<b>Filters:</b> English. <b>Results: 289,296</b></p> <p><b>AND</b></p> <p><b>#4:</b> (((((((((kidney sparing) OR (renal sparing)) OR (nephron sparing)) OR (kidney preserving)) OR (renal preserving)) OR (nephron preserving)) OR (laparoscopic partial nephrectomy)) OR (3D laparoscopic partial nephrectomy)) OR (robotic partial nephrectomy)) OR (robotic assisted partial nephrectomy)) OR (ablation) <b>Filters:</b> English. <b>Results: 131,212</b></p> <p><b>Final Query #5:</b> (((((((((((((kidney sparing) OR (renal sparing)) OR (nephron sparing)) OR (kidney preserving)) OR (renal preserving)) OR (nephron preserving)) OR (laparoscopic partial nephrectomy)) OR (3D laparoscopic partial nephrectomy)) OR (robotic partial nephrectomy)) OR (robotic assisted partial nephrectomy)) OR (ablation) AND (english[Filter])) AND (((((((minimal invasive) OR (laparoscopic)) OR (3D laparoscopic)) OR (robotic)) OR (robotic assisted)) OR (ablation) AND (english[Filter])) AND (((((((endophytic) OR (intraparenchymal)) OR (intrarenal)) OR (parenchymal) AND (english[Filter])) AND (((((((renal tumor) OR (renal mass)) OR (renal lesion)) OR (renal cancer)) OR (kidney tumor)) OR (kidney mass)) OR (kidney lesion)) OR (kidney cancer) AND (english[Filter])) <b>Filters:</b> English. <b>Results: 409</b></p>	English	409
Cochrane Library	renal tumor OR renal mass OR renal lesion OR renal cancer OR kidney tumor OR kidney mass OR kidney lesion OR kidney cancer in Title Abstract Keyword AND endophytic OR intraparenchymal OR intrarenal OR parenchymal in Title Abstract Keyword AND minimal invasive OR laparoscopic OR 3D laparoscopic OR robotic OR robotic assisted OR ablation in Title Abstract Keyword AND kidney sparing OR renal sparing OR nephron sparing OR kidney preserving OR renal preserving OR nephron preserving OR laparoscopic partial nephrectomy OR 3D laparoscopic partial nephrectomy OR robotic partial nephrectomy OR robotic assisted partial nephrectomy OR ablation in Title Abstract Keyword - (Word variations have been searched)	English	20
Google Scholar	Keywords: tumor marking endophytic renal tumor minimal invasive kidney sparing	English	977
Web of science	renal tumor OR renal mass OR renal lesion OR renal cancer OR kidney tumor OR kidney mass OR kidney lesion OR kidney cancer in Title Abstract Keyword AND endophytic OR intraparenchymal OR intrarenal OR parenchymal in Title Abstract Keyword AND minimal invasive OR laparoscopic OR 3D laparoscopic OR robotic OR robotic assisted OR ablation in Title Abstract Keyword AND kidney sparing OR renal sparing OR nephron sparing OR kidney preserving OR renal preserving OR nephron preserving OR laparoscopic partial nephrectomy OR 3D laparoscopic partial nephrectomy OR robotic partial nephrectomy OR robotic assisted partial nephrectomy OR ablation	Title search	29



**Table 1.** Summary of results from studies regarding Laparoscopic-assisted Partial Nephrectomy (LPN) for endophytic tumors.

Study	Study type	Endophytic	Multivariate regression	Study arms	Laparoscopic technique	Identification method	Identification	Mean endophytic	Positive	Complications	Recurrence	Overall mean
Ga et al.2020 <sup>(22)</sup>	Retrospective	61/112	R.E.N.AL. Score/	RAPN VS LPN for	LPN	IOUS	51(100)	25	1(1.96)	10(19.6%)	0	39.2
Qin et al.2018 <sup>(23)</sup>	Retrospective	46/583 <sup>c</sup>	NA	TIT VS exophytic	retroLPN	IOUS	46(100)	24.2	0	7(15.2) <sup>d</sup>	0	NA
Di Piero et al.2014 <sup>(24)</sup>	Retrospective	11/11 <sup>c</sup>	NA	Single arm	retroLPN	IOUS	11(100)	16	1(9)	2(18)	0	34
Gao et al.2014 <sup>(25)</sup>	Prospective	2/55	NA	Single arm	LPN	IOUS and Hydro-Jet excision	2(100)	NA	0	NA	0	6.32
Engel et al.2013 <sup>(18)</sup>	Retrospective	8/8	NA	Single arm	Unclamped hand-assisted	IOUS	8(100)	37	1(12.5)	2(25)	NA	3
Nadu et al.2013 <sup>(14)</sup>	Retrospective	41/402 <sup>e</sup>	NA	TIT VS any exophytic	transLPN	IOUS	41(100)	26	2(5.4)	68(18.7%)	0	26
Chung et al.2011 <sup>(15)</sup>	Retrospective	55/800 <sup>f</sup>	No covariates significant/	Intraparenchymal VS any	retroLPN and transLPN	IOUS	55(100)	23	0	13(23.6%) <sup>d</sup>	NA	NA
Shikanov et al.2009 <sup>(21)</sup>	Prospective	32/184 <sup>f</sup>	NA	Single arm	transLPN	IOUS	NA	NA	NA	19(66) <sup>f</sup>	NA	NA
Venkatesh et al.2006 <sup>(19)</sup>	Retrospective	19/123 <sup>g</sup>	NA	Exophytic VS mesophytic VS	transLPN and retroLPN	IOUS	NA	23.1	2(10.5)	9(47.4)	0	16
Fazio et al.2006 <sup>(20)</sup>	Retrospective	3/50	NA	LPN VS LRN VS lap	LPN	IOUS and percutaneous delineation	3(100)	NA	0	NA	0	27
Wang et al.2019 <sup>(42)</sup>	Retrospective	6/49	Parenchymal mass	3D reconstruction	transLPN or retroLPN	AR: 3D reconstruction manual registration	6(100)	NA	0	NA	NA	NA
Zhang et al.2018 <sup>(6)</sup>	Retrospective	15/91 <sup>h</sup>	NA	Single arm	LPN	AR: 3D reconstruction manual	15(100)	NA	0	NA	NA	NA
Fin et al.2018 <sup>(31)</sup>	Retrospective	5/5	NA	Single arm	transLPN or retroLPN	3D printing physical kidney model	5(100)	27.8	0	0 <sup>i</sup>	NA	NA
Wang et al.2015 <sup>(44)</sup>	Retrospective	8/35	NA	3D-MIRGS VS no 3D	3D-retroLPN	AR: 3D reconstruction manual registration	8(100)	NA	0	NA	NA	6
Chen et al.2014 <sup>(47)</sup>	Retrospective	15/15	NA	Single arm	retroLPN	AR: 3D reconstruction manual registration	15(100)	27	0	2(13.3) <sup>j</sup>	0	12
Simplendorfer et al.2016 <sup>(37)</sup>	Retrospective	NA/10 <sup>f</sup>	NA	Single arm	transLPN	AR: manual registration with	10(100)	NA	0	0	0	17
Teber et al.2009 <sup>(36)</sup>	Retrospective	10/10	NA	Single arm	retroLPN	AR: Manual registration with CB	10(100)	38	0	0	NA	NA
Shao et al.2012 <sup>(30)</sup>	Retrospective	25/125 <sup>g</sup>	Tumor location and	Single arm	retroLPN	DSCT angiography	25(100)	NA	0	NA	0	18
Hernandez et al.2017 <sup>(45)</sup>	Case report	1/3	NA	Single arm	transLPN	ROLL	1(100)	NA	NA	NA	NA	NA
Kouris et al.2019 <sup>(33)</sup>	Case report	1/1	NA	Single arm	transLPN	Perc Hook-Wire	1(100)	33	0	0	0	16
Mandoorah et al.2018 <sup>(32)</sup>	Case report	1/1	NA	Single arm	transLPN	Perc Hook-Wire	1(100)	16	0	0	0	NA
Bouvier et al.2020 <sup>(34)</sup>	Prospective	7/50	NA	Single arm	LPN	Blue dye embolization	NA	NA	0	0 <sup>m</sup>	0	1

a=endophytic refers to totally intrarenal tumors with no exophytic component, b=not included 4 radical nephrectomy conversions and 1 open conversion, c=all endophytic tumors were hilar, d=endophytic tumors were totally intraparenchymal not visualized in the kidney surface, e=endophytic defined as >66% of tumor volume embedded in parenchyma, f=5 conversions to open surgery are included with 14 intraoperative and postoperative complications, g=endophytic defined as <40% of the lesion extending off the kidney surface, h=endophytic defined as <40% mass protruding, i= Clavien >II, j=postoperative only, k= lesion extending <40% from the kidney

Table 2. Summary of results from studies regarding Robotic-Assisted Partial Nephrectomy (RAPN) for endophytic tumors.												
Study	Study type	Endop. rate	Multivariate regression	Study arms	Surgical approach	Identification method	Identification rate	Mean endop. rate	Positive %	Conversion %	Recurrence rate	Overall survival
Gu et al.2020 <sup>(12)</sup>	Retrospective	61/112	REN, AL, S, m, n	RAPN VS LPN for comparable	RAPN	IOUS	61(100)	23	2(3.27)	50(82)	0	27.3
Tiryaki et al.2018 <sup>(66)</sup>	Case report	1/1	NA	-	transRAPN	IOUS with Doppler	1(100)	24	0	0	0	12
Abdel Raheem et al.2018 <sup>(65)</sup>	Retrospective	52/89	NA	RAPN VS OPN for comparable	transRAPN	IOUS and Frozen	NA	28	5(9.6)	17(32.7)	2(3.9) <sup>e</sup>	59
Harke et al.2018 <sup>(46)</sup>	Retrospective	64/140	PADUA score/ TRIFECTA	RAPN VS OPN for comparable	transRAPN	IOUS and Frozen	64(100)	26	0	14(21.9)	NA	NA
Gunelli et al.2016 <sup>(49)</sup>	Retrospective	NA/22	NA	Single arm	Robotic enucleation	RobIOUS	22(100)	NA	0	0	NA	NA
Kara et al.2016 <sup>(48)</sup>	Retrospective	87/143	NA	RAPN VS OPN for comparable	RAPN	IOUS	NA	28	4(5.4)	19(21.8)	0	15.2
Curtiss et al.2015 <sup>(51)</sup>	Retrospective	30/297	NA	Intra renal VS exophytic tumors	3 or 4-arm transRAPN	ILUS or rob IIOUS	NA	23	0	2(6.67)	0	10.6
Boylu et al.2015 <sup>(52)</sup>	Retrospective	8/66	NA	RAPN VS OPN for comparable	transRAPN	IOUS	NA	NA	NA	NA	0	33
Shiroki et al.2015 <sup>(43)</sup>	Retrospective	4/48	Tumor-attached	long WIT VS Short WIT	Trans or transRAPN	IOUS	NA	NA	0	0	NA	NA
Kominos et al.2014 <sup>(44)</sup>	Retrospective	45/225	Age and RENAL	Endophytic VS exophytic VS mesenchymal VS	transRAPN	ILUS and frozen biopsies	44(97.8) <sup>y</sup>	26	1(2.2) <sup>z</sup>	12(26.7) <sup>y</sup>	1(2.2)	48
Antonino et al.2014 <sup>(45)</sup>	Prospective	65/389	NA	Endophytic VS exophytic VS	transRAPN	IOUS	65(100)	26	3(4.6)	8(12.3) <sup>y</sup>	1(1.6)	12.6
Kaczmarek et al.2013 <sup>(41)</sup>	Retrospective	49/150 <sup>h</sup>	NA	Robotic VS laparoscopic IUS	Trans and retro RAPN	RobIOUS and ILUS	NA	NA	3(6.1)	NA	0	18 <sup>i</sup>
Kaczmarek et al.2012 <sup>(42)</sup>	Retrospective	21/22 <sup>h</sup>	NA	Single arm	3-arm transRAPN	RobIOUS	21(100)	NA	0	NA	0	13
Kim et al.2012 <sup>(45)</sup>	Retrospective	9/65	NA	Complex VS not complex tumors in	Off-clamp Trans and	RobIOUS	9(100)	NA	NA	NA	0	14
White et al.2011 <sup>(47)</sup>	Retrospective	3/67	NA	Single arm	transRAPN	ILUS	3(100)	NA	NA	NA	0	8
Hyams et al.2011 <sup>(48)</sup>	Prospective	12/53	NA	LDU VS no-LDU in RAPN	RAPN	ILUS with Doppler	NA	33 <sup>j</sup>	NA	0	NA	NA
Rogers et al.2008 <sup>(49)</sup>	Retrospective	4/14	NA	Single arm	transRAPN	ILUS	4(100)	32.5	0	0	0	3
Gong et al.2009 <sup>(48)</sup>	Retrospective	12/32	NA	Single arm	4-arm transRAPN	ILUS	NA	NA	0	0	0	15
Ho et al.2009 <sup>(49)</sup>	Retrospective	6/20	NA	Single arm	3-arm transRAPN	ILUS	6(100)	NA	0	0	0	12
Alenezi et al.2016 <sup>(48)</sup>	Retrospective	5/61	NA	Global VS selective VS no ischemia	4-arm transRAPN	robIOUS and CEUS	5(100)	NA	NA	NA	NA	18.5
Simone et al.2018 <sup>(70)</sup>	Prospective	10/10	NA	Single arm	Off-clamp transRAPN	TAE NIRE-ICG	10(100)	30	0	0	0	12
Angeli et al.2013 <sup>(48)</sup>	Retrospective	2/79	NA	Single arm	transRAPN	IV NIRE-ICG and Doppler	0 <sup>n</sup>	NA	0	NA	NA	NA
Krane et al.2012 <sup>(48)</sup>	Prospective	5/47	NA	NIRE-ICG VS no NIRE-ICG RAPN	4-arm RAPN	IV NIRE-ICG and Doppler	0 <sup>n</sup>	NA	NA	NA	NA	5
Porpiglia et al.2019 <sup>(71)</sup>	Retrospective	28/91	NA	3D AR VS US	transRAPN	AR: HA3D navigation for	28(100)	NA	NA	NA	0	3
Porpiglia et al.2018 <sup>(71)</sup>	Prospective	12/52	NA	HA3D VS no HA3D guidance for selective	transRAPN	AR: HA3D navigation and	12(100)	NA	0	NA	NA	NA
Laaser et al.2012 <sup>(77)</sup>	Retrospective	2/10	NA	Single arm	RAPN	AR: real-time IIOUS and VSP	2(100)	NA	0	0	NA	4
Reeves et al.2015 <sup>(79)</sup>	Case report	1/1	NA	-	retroRAPN	Percutaneous embolization	1(100)	25	0	0	NA	NA

**a**=5 intraoperative complications (3 conversions, 1 ureteric injury, 1 transfusion), 12 postoperative complications (2 ≥III), **b**=1 local recurrence, 1 metastasis, **c**=1 intraoperative, 18 postoperative complications (4 III-IV), **d**=1 tumor positive frozen biopsy, 97.8% technical success, **e**= 1 tumor positive frozen biopsies, conversion, **f**=3 intraoperative (2 conversion, 1 ureteric injury) and 9 postoperative (4 I, 3 II, 2 III), **g**=2 intraoperative and 6 postoperative (1 III-IV), **h**=20 tumors >50% endophytic in the laparoscopic IOUS and 29 in robotic IOUS, **i**= 75 underwent RAPN with robotic IOUS and 75 with laparoscopic IOUS, **j**=25.7 months in the laparoscopic IOUS and 10.3 months in the robotic IOUS, **k**=endophytic: ≥50% endophytic component, **l**=32mm in LDU, 34mm in non LDU, **m,n**= detection with IOUS, no fluorescence of ICG, **o**=HA3D identified all endophytic masses before fat detachment allowing no kidney rotation.

a=5 intraoperative complications (3 conversions, 1 ureteric injury, 1 transfusion), 12 postoperative complications (2 ≥III), b=1 local recurrence, 1 metastasis, c=1 intraoperative, 18 postoperative complications (4 III-IV), d=1 tumor positive frozen biopsy, 97.8% technical success, e= 1 tumor positive frozen biopsies, conversion, f=3 intraoperative (2 conversion, 1 ureteric injury) and 9 postoperative (4 I, 3 II, 2 III), g=2 intraoperative and 6 postoperative (1 III-IV), h=20 tumors >50% endophytic in the laparoscopic IIOUS and 29 in robotic IIOUS, i= 75 underwent RAPN with robotic IIOUS and 75 with laparoscopic IIOUS, j=25,7 months in the laparoscopic IIOUS and 10,3 months in the robotic IIOUS, k=endophytic: ≥50% endophytic component, l=32mm in LDU, 34mm in non LDU, m,n= detection with IIOUS, no fluorescence of ICG, o=HA3D identified all endophytic masses before fat detachment allowing no kidney rotation.

Table 3. Endophytic tumor localization techniques during ablation procedures.										
Study	Study type	Endophytic	Study arms	Ablation	Identification	Technical	Endophytic	Complication	Recurrence	Overall mean
Radiofrequency Ablation (RFA)										
Sommer et al.2017 <sup>(88)</sup>	Systematic Review	NA	-	PRFA	iodized oil	NA	NA	NA	NA	NA
Cupia et al.2009 <sup>(82)</sup>	MI, prospective	46/163	Single arm	PRFA	G.A and real-time	43(93.48)	NA	NA	4(8.7) <sup>e</sup>	20.3
Gervais et al.2005 <sup>(83)</sup>	Retrospective case-	5/100	Single arm	PRFA	CT or US	5(100)	NA	NA	NA	27.6
Farrell et al.2003 <sup>(84)</sup>	Retrospective case-	13/35	Single arm	PRFA	G.A and CT or	13 (100)	NA	0 <sup>f</sup>	0	9
Veltri et al.2004 <sup>(87)</sup>	Retrospective case-	9/18 <sup>e</sup>	Single arm	PRFA	US	9(100)	26.9	0	0 <sup>f</sup>	14
Pietryga et al.2012 <sup>(86)</sup>	Retrospective case-	8/46	Coil VS no	PRFA	Embolization	8(100)	NA	0	0	4
Matsumoto et al.2004 <sup>(85)</sup>	Retrospective case-	17/64	Single arm	PRFA/LRFA/o	CT/IOUS/NA	16(94.1)	NA	NA	1 (5.9)	12 <sup>d</sup>
Young E. et al.2012 <sup>(81)</sup>	Retrospective	48/316	PRFA VS	(25) PRFA/(23)	G.A and	NA	NA	NA	NA	NA
Wingo et al.2008 <sup>(85)</sup>	Prospective	41/146	PRFA VS	(21)PRFA/(20)	F-CT/IOUS or	37(90.2)	27	8 (19.5)	4(9.75)	29
Jacomides et al.2003 <sup>(89)</sup>	Retrospective	2/17	In situ LRFA	(2) In situ	IOUS	2 (100)	21	0	0	9.8
Zelsher et al.2007 <sup>(90)</sup>	Prospective case-	5/32	Single arm	RFA –assisted	IOUS	4(80)	NA	NA	0	36
Yang et al.2014 <sup>(86)</sup>	Retrospective case-	NA/51	Single arm	LRFA	CEUS	NA	NA	NA	NA	31.5
Wu et al.2010 <sup>(95)</sup>	Prospective	31/78	LPN VS RF-	(5) LPN/(26)	ILUS	26(100)	NA	NA	0 <sup>f</sup>	7.8
Nadler et al.2009 <sup>(91)</sup>	Retrospective case-	NA/16	Single arm	RFA assisted	ILUS	NA	NA	NA	NA	NA
Cryoablation										
Murray et al.2019 <sup>(86)</sup>	Retrospective case-	49/49	Single arm	PCA	US or F-CT	49(100)	25	5 (10) <sup>b</sup>	6(13) <sup>f</sup>	56.5
Azevedo et al.2018 <sup>(92)</sup>	Retrospective case-	27/71	Single arm	PCA	US and CT	NA	NA	8(32) <sup>f</sup>	NA	NA
Pempongkosol et al.2006 <sup>(88)</sup>	Retrospective case-	8/23	Single arm	PCA	F-CT	6(75)	27	1(12.5)	NA	2.7
Michimoto et al.2016 <sup>(90)</sup>	Retrospective case-	17/17	Single arm	PCA	Ethanol and iodized	16(94.12)	26.5	0	5(29.4) <sup>f</sup>	15.4
Kajiwara et al.2020 <sup>(91)</sup>	Retrospective case-	11/13 <sup>f</sup>	Single arm	PCA	Ethanol and	11(100)	NA	0	0	11.5
Hamon et al.2018 <sup>(93)</sup>	Case report	1/1	Single arm	PCA	polyvinyl	1(100)	39.9	0	0	4
Atwell et al.2008 <sup>(99)</sup>	Retrospective case-	28/115	Single arm	PCA	US and CT	NA	NA	1(3.57)	NA	13.3
Wright et al.2007 <sup>(100)</sup>	Retrospective case-	3/35	Single arm	LCA	IOUS	1(33.4)	NA	0	0	18
Mues et al.2010 <sup>(104)</sup>	Retrospective	38/171	PCA VS LCA	(16)PCA/(22)	F-CT/ILLUS	NA	NA	NA	0/NA	NA
Derweesh et al.2008 <sup>(106)</sup>	Retrospective	5/60	CI guided PCA	(2)PCA/(3)LC	F-CT/ILLUS	5(100)	NA	NA	2 (40), 1 in lap	12/6
Microwave Ablation (MWA)										
Yu et al.2012 <sup>(106)</sup>	Retrospective case-	44/49	Single arm	PMWA	US and FOTM	26	18	0	3 endophytic	Parenchymal 17.9,
All thermal ablation techniques										
Zhou et al.2017 <sup>(97)</sup>	Retrospective	18/49	PMWA/RFA/	PMWA/RFA/	CT	18(100)	NA	NA	NA	37.2
Zhou et al. 2018 <sup>(108)</sup>	Retrospective	90/437	PMWA/RFA/	(12) PMWA	CT	90(100)	NA	0 <sup>g</sup>	NA	11
Zhou et al.2019 <sup>(109)</sup>	Retrospective	57/297	PMWA/RFA/	(7) PMWA	CT	57(100)	NA	0 <sup>g</sup>	NA	24
Irreversible Electroporation (IRE)										
Diehl et al. 2016 <sup>(110)</sup>	Retrospective case-	NA/7	Single arm	IRE	CT	7(100) <sup>g</sup>	NA	0 <sup>g</sup>	NA	6.4
High Intensity Focused Ultrasound (HIFU)										
Ritche et al. 2010 <sup>(111)</sup>	Retrospective case-	5/17	Single arm	HIFU	US	1(20)	20.4	0	1 (25) <sup>f</sup>	36

a=2 local recurrence-3,24 months, 2 metastases -4,5 and 12 months , b= No major complications, d=only 8/17 endophytic tumors had follow up 12 months, e= 9 parenchymal without exophytic part, f= 1 death at 6 months follow up due to metastatic lung cancer, g=no local recurrence, 1 distant of unknown endophytic status, h= 5 /48 procedures showed major complications, i= 6/46 tumors local recurrence , Follow-up ≥3 months, following ablation, j= 8/25, k= 1 local recurrence in 12 month follow-up, 4 metastasis, l= 8 endophytic, 3 entirely endophytic, m= no II-IV complications, n= no II-IV complications, only for MWA group, o= tumor response rate=technical success rate, p= no major complications, r= 1 recurrence (20% size increase at 6 month Follow-up), i in 4 tumors with HIFU, defined as 20% increase in size at 6 months follow-up.

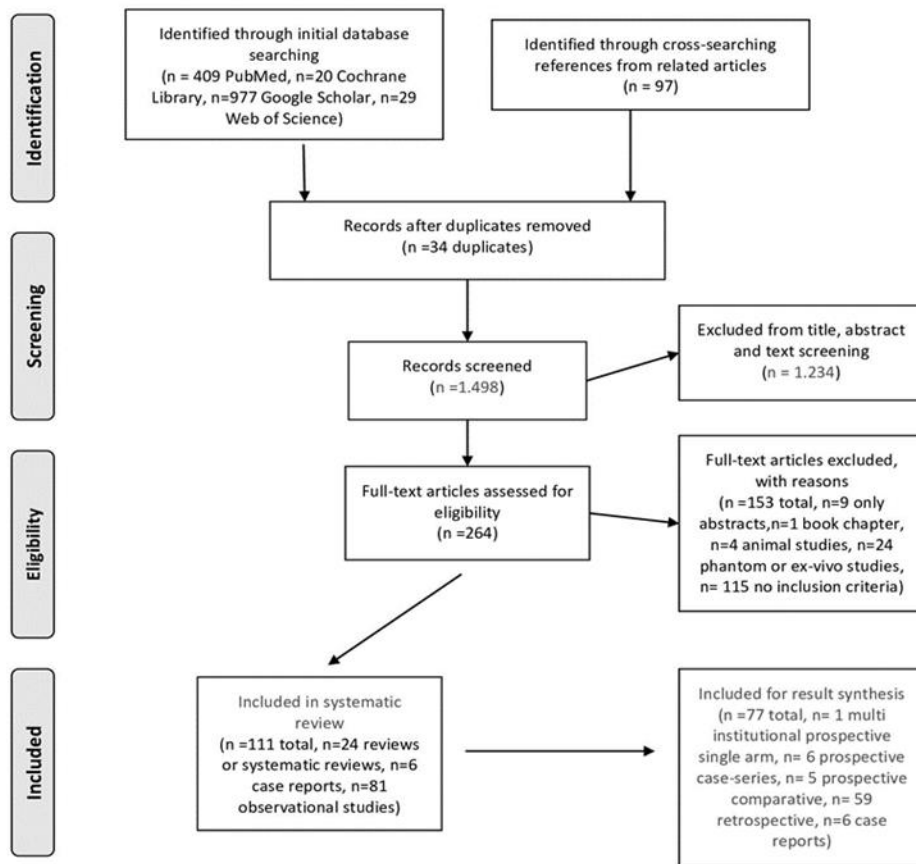


Table 4: Results of meta-regression subgroup analysis for the five individual meta-analysis scopes. The model slope is presented in separate columns for the binary variables depending on their value (YES or NO). Statistically significant p values are presented in bold.														
		$\tau^2$ (estimated amount of residual heterogeneity)	p (test for residual heterogeneity)	I <sup>2</sup> (residual heterogeneity / unaccounted variability)	H <sup>2</sup> (unaccounted variability / sampling variability)	R <sup>2</sup> (amount of heterogeneity accounted for)	Model intercept	intercept p	Model slope	Slope p	For binary repressor variables			
Scope	Regression variable										Model slope (NO)	Slope (NO) p	Model slope (YES)	Slope (YES) p
Positive margins laparoscopic	Tumor size	0	0.7848	0.00%	1.0	0%	-2.3	0.5769	0.69	0.6315				
	Tumor location (anterior, posterior, central, hilar)	No data												
	B.M.I	No data												
	R.E.N.A.L score	No data												
	Ischemia Time	0	0.7324	0.00%	1.0	0%	0.3	0.9761	-0.02	0.1280				
	Resection time	No data												
Positive margins robotic	Tumor size	0.2	0.2936	18.46%	1.2	0%	-0.6	0.8380	0.34	0.7406				
	Tumor location (anterior, posterior, central, hilar)	No data												
	B.M.I	0	0.7973	0.00%	1.0	100%	10.1	<b>0.0231</b>	-0.37	<b>0.0294</b>				
	R.E.N.A.L score	0.2	0.3088	16.29%	1.2	0%	2.3	0.5080	-0.30	0.5596				
	PADUA score	No data												
	Ischemia Time	0	-		1.0	-3.9	0.2	0.1887	0.19	0.1442				
	Resection time	No data												
	Positive margins	No data												
	Tumor location (anterior, posterior, central, hilar)	No data												
Recurrence robotic	R.E.N.A.L score	No data												
	Histological type	No data												
	Stage	No data												
	Grade	No data												
	Age	No data												
Recurrence laparoscopic	Due to no recurrences reported in the studies, meta-analysis/regression was not performed													
Technical success ablation	Tumor size	3.5	0.0534	57.11%	2.3	0%	-0.6	0.6611	0.04	0.6572				
	Intraoperative fluoroscopy	3.5	0.0521	57.40%	2.4	0%	0.4	0.8200			-0.88	0.686		
	Procedures under General Anesthesia	4.5	<b>0.0431</b>	63.16%	2.7	0%	1.3	0.6389			-0.86	0.7937	-2.13	0.4551
	Preoperative CT Hounsfield units	No data												
	Hydro-dissection	3.5	0.0559	56.60%	2.3	0%	-0.4	0.7158					1.27	0.6351
	Number of Ablation probe insertions	No data												
	Number of needles	0	0.5271	0.00%	1.0	100%	6.1	<b>0.0314</b>	-2.80	<b>0.0118</b>				
	Ablation time	3.3	0.0604	55.69%	2.3	0%	1.2	0.6507	-0.07	0.5729				
	Ablation power applied (Kw)	No data												

**Tables’s abbreviations**CE-CT=Contrast enhanced CT, **NA**= Not Assessed, data absent or inconclusive, **n.** =number, **OPN**= Open partial nephrectomy, **perc**=percutaneous, **RFA**= Radiofrequency ablation **RF-RCPN**= Radiofrequency ablation –assisted robotic clampless partial nephrectomy, **retro**= retroperitoneal, **TIT**= Totally intraparenchymal tumors, **trans**= trans peritoneal, **VSP**= Virtual surgical planning, **VS**= Versus, **WIT**= Warm ischemia time

## Appendix B

**Figure 1.** Search strategy presented with PRISMA flow-chart.



From: Moher D, Liberati A, Tetzlaff J, Altman DG, The PRISMA Group (2009). Preferred Reporting Items for Systematic Reviews and Meta-Analyses: The PRISMA Statement. PLoS Med 6(7): e1000097. doi:10.1371/journal.pmed1000097

For more information, visit [www.prisma-statement.org](http://www.prisma-statement.org).

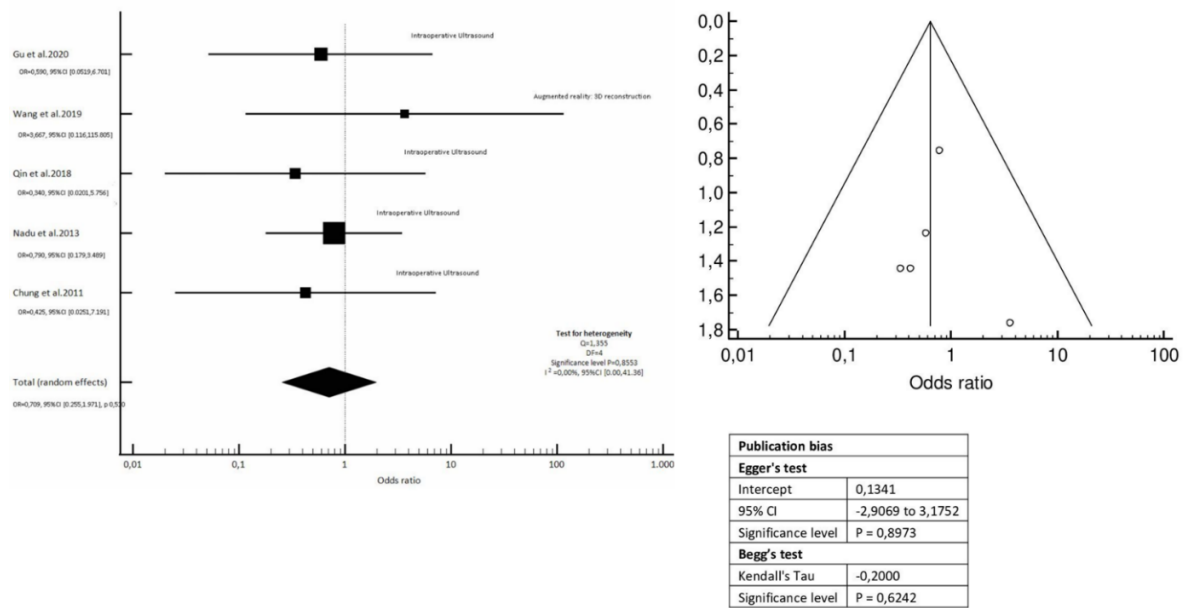
**Figure 2.** Risk of Bias Traffic-light plot created with ROBVIS tool. Assessment of bias for each non-randomized study throughout seven domains of bias (D1-D7). Domains are stratified with a judgment from low to serious.

		Risk of bias domains							
		D1	D2	D3	D4	D5	D6	D7	Overall
Study	Gu et al. 2020	⊗	+	-	⊗	+	+	+	⊗
	Murray et al. 2019	⊗	+	-	⊗	⊗	+	+	⊗
	Simone et al. 2018	-	+	+	+	+	+	+	-
	Michimoto et al. 2016	⊗	-	+	+	⊗	⊗	⊗	⊗
	Chen et al. 2014	⊗	+	+	+	+	⊗	⊗	⊗
	Autorino et al. 2014	-	+	+	+	+	+	+	-
	Di Piero et al. 2014	⊗	-	+	+	+	+	-	⊗
	Komninos et al. 2014	⊗	-	+	+	+	+	+	⊗
	Nadu et al. 2013	⊗	+	+	+	-	+	+	⊗
	Ritchie et al. 2010	⊗	⊗	+	+	⊗	⊗	⊗	⊗
	Rogers et al. 2008	⊗	⊗	+	+	-	-	+	⊗
	Wingo.et al 2008	-	-	⊗	⊗	+	-	⊗	⊗
	Veltri et al. 2004	⊗	⊗	+	+	⊗	-	⊗	⊗
	Jacomides et al. 2003	⊗	⊗	⊗	⊗	-	+	+	⊗

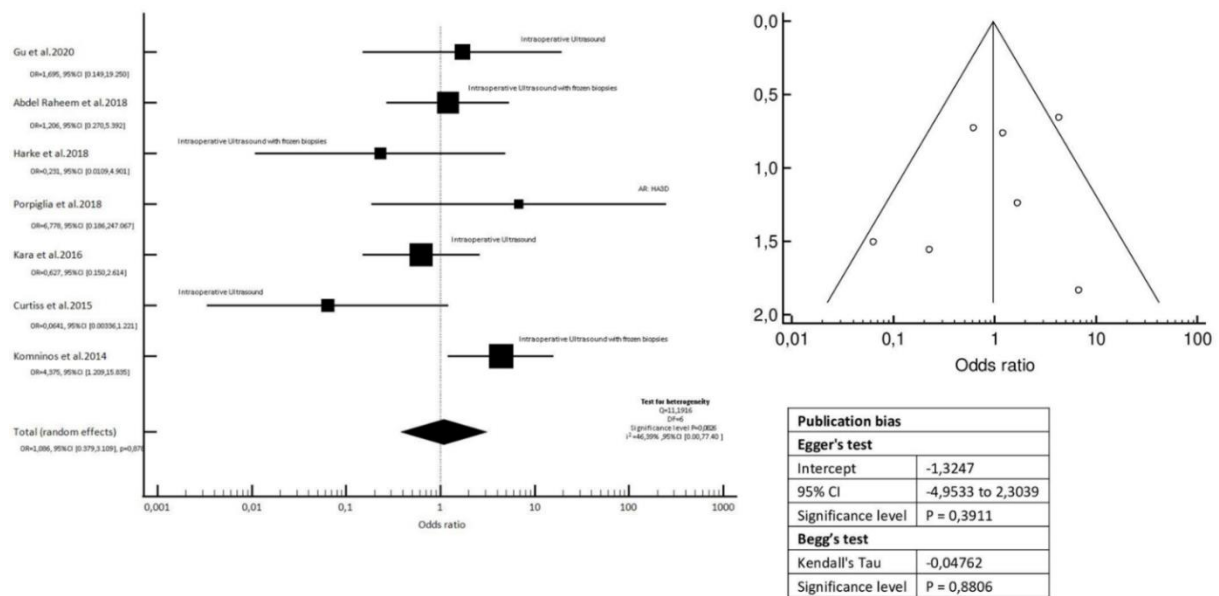
Domains:  
D1: Bias due to confounding.  
D2: Bias due to selection of participants.  
D3: Bias in classification of interventions.  
D4: Bias due to deviations from intended interventions.  
D5: Bias due to missing data.  
D6: Bias in measurement of outcomes.  
D7: Bias in selection of the reported result.

Judgement  
⊗ Serious  
- Moderate  
+ Low

**Figure 3.** Odds Ratio Forest-plot for positive surgical margins after Laparoscopic partial nephrectomy for completely endophytic tumors. OR calculated overall and separately for positive margins using different localization techniques.  $I^2$  shows low heterogeneity of data. Funnel-plot, Egger's test and Begg's test were used for publication bias evaluation.

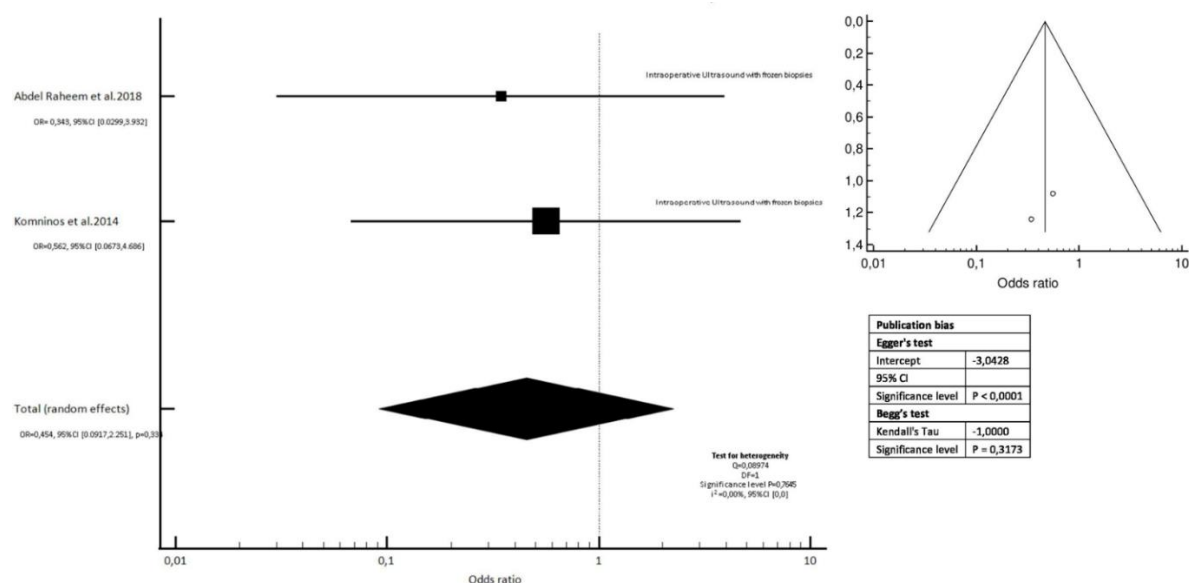


**Figure 4.** Odds Ratio Forest-plot for positive surgical margins after Robotic partial nephrectomy for completely endophytic tumors. OR calculated overall and separately for positive margins using different localization techniques.  $I^2$  shows moderate heterogeneity of data. Funnel-plot, Egger's test and Begg's test were used for publication bias evaluation.

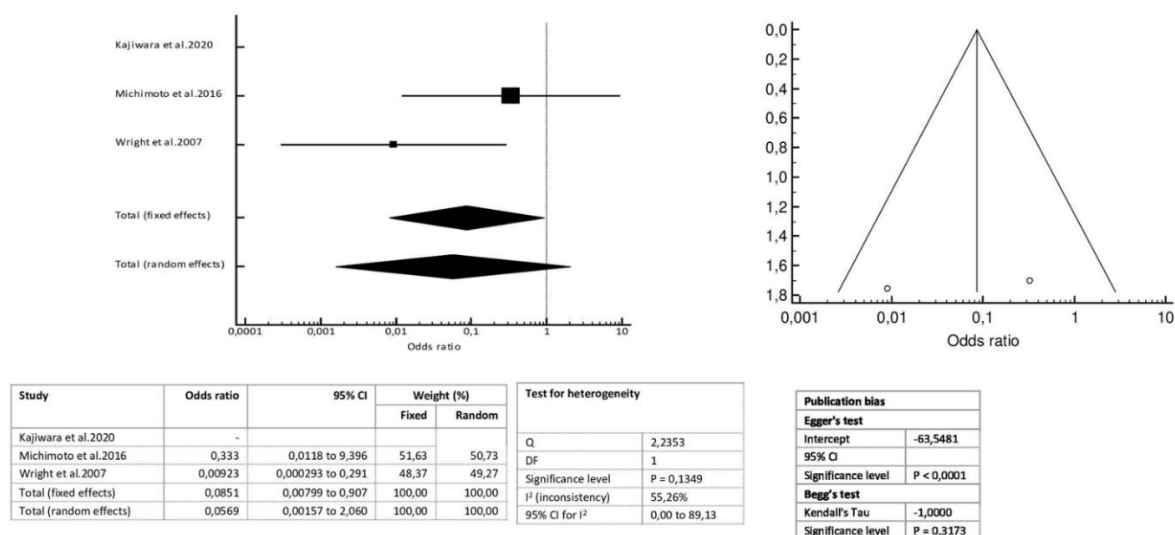


**Figure 5.** Odds Ratio Forest-plot depicting likelihood for tumor recurrence using intraoperative ultrasound guidance with frozen samples from tumor bed in Robotic Partial Nephrectomy for completely endophytic tumours.

$I^2$  shows low heterogeneity of data. Funnel-plot, Egger's test and Begg's test were used for publication bias evaluation.



**Figure 6.** Invasive techniques in Ablation procedures. Forest-plot depicting odds ratios for technical success during thermal ablation procedures for completely endophytic tumors. Cochran's Q test and  $I^2$  statistic are calculated for heterogeneity. Funnel-plot, Egger's test and Begg's test show publication bias.



**Figure 7.** Non-invasive techniques in Ablation procedures. Forest-plot depicting odds ratios for technical success during thermal ablation procedures for completely endophytic tumors. Cochran's Q test and  $I^2$  statistic are calculated for heterogeneity. Funnel-plot, Egger's test and Begg's test show publication bias.

